

# Pancreas Divisum as a Rare Etiology of Recurrent Pancreatitis: A Rare Case Ever Documented and Reported In Indonesia

*M. Begawan Bestari\**, *Eka Surya Nugraha*, *Siti Aminah Abdurachman*

Division of Gastroenterohepatology, Department of Internal Medicine, Hasan Sadikin General Hospital-Faculty of Medicine Universitas Padjadjaran, Bandung, Indonesia.

## \*Corresponding Author:

*M. Begawan Bestari, MD, PhD, FASGE. Division of Gastroenterohepatology, Department of Internal Medicine, Faculty of Medicine Universitas Padjadjaran - Hasan Sadikin Hospital. Jl. Pasteur no. 38, Bandung, Indonesia. Email: [begawan@gmail.com](mailto:begawan@gmail.com).*

## ABSTRACT

*Pancreas divisum is an abnormal condition of pancreas duct that occurs from organogenesis. This abnormal condition defined as a failure in fusion between dorsal and ventral part of the pancreas. The incidence reported 4%-14% in general population. Majority patient with pancreas divisum will not present with any sign or symptom, but in some cases may present with signs of pancreatitis. We illustrate a case of 39 years old male with pancreas divisum presenting as acute recurrent pancreatitis. Diagnosis of pancreas divisum was determined through magnetic resonance cholangiopancreatography (MRCP) and endoscopic retrograde cholangiopancreatography (ERCP). Patient treated by sphincterotomy and dilation using Soehendra's dilator catheter. This is the first pancreas divisum case successfully treated and reported in Indonesia.*

*Keywords: ERCP, pancreas divisum, pancreatitis, sphincterotomy.*

## INTRODUCTION

Pancreas divisum is the most common congenital anomaly of pancreas that can be found in around 4%-14% of the population by cadaveric examination.<sup>1</sup> In Asia, this congenital anomaly was reported in 0.5%-3.7% patients who underwent endoscopy.<sup>2</sup> Pancreas divisum is defined as an abnormal condition caused by failure of fusion between two embryonic parts of the pancreas. In normal development, ventral bud of pancreas will rotate around foregut and fuse with dorsal bud of pancreas during the seventh gestational week. This fusion allows the ventral duct and dorsal duct to form the main pancreatic duct or Wirsung duct and later will join with the common bile duct and drains into the major papilla, which in normal pancreas drains through this duct. The remaining dorsal duct known as Santorini duct, will drain through minor papilla.

In pancreas divisum, ventral and dorsal buds fail to fuse and form anomaly that are classified into three major types. Type I (classic pancreatic divisum) is a complete failure of fusion identified by non-union of ventral and dorsal ducts. Type II pancreatic divisum is characterized by the absence of ventral duct with dominant dorsal drainage. Type III or incomplete pancreas divisum described as a presence of rudimentary communication between dorsal duct and ventral ducts.<sup>3</sup> This is a case report of pancreas divisum which presents with recurrent pancreatitis.

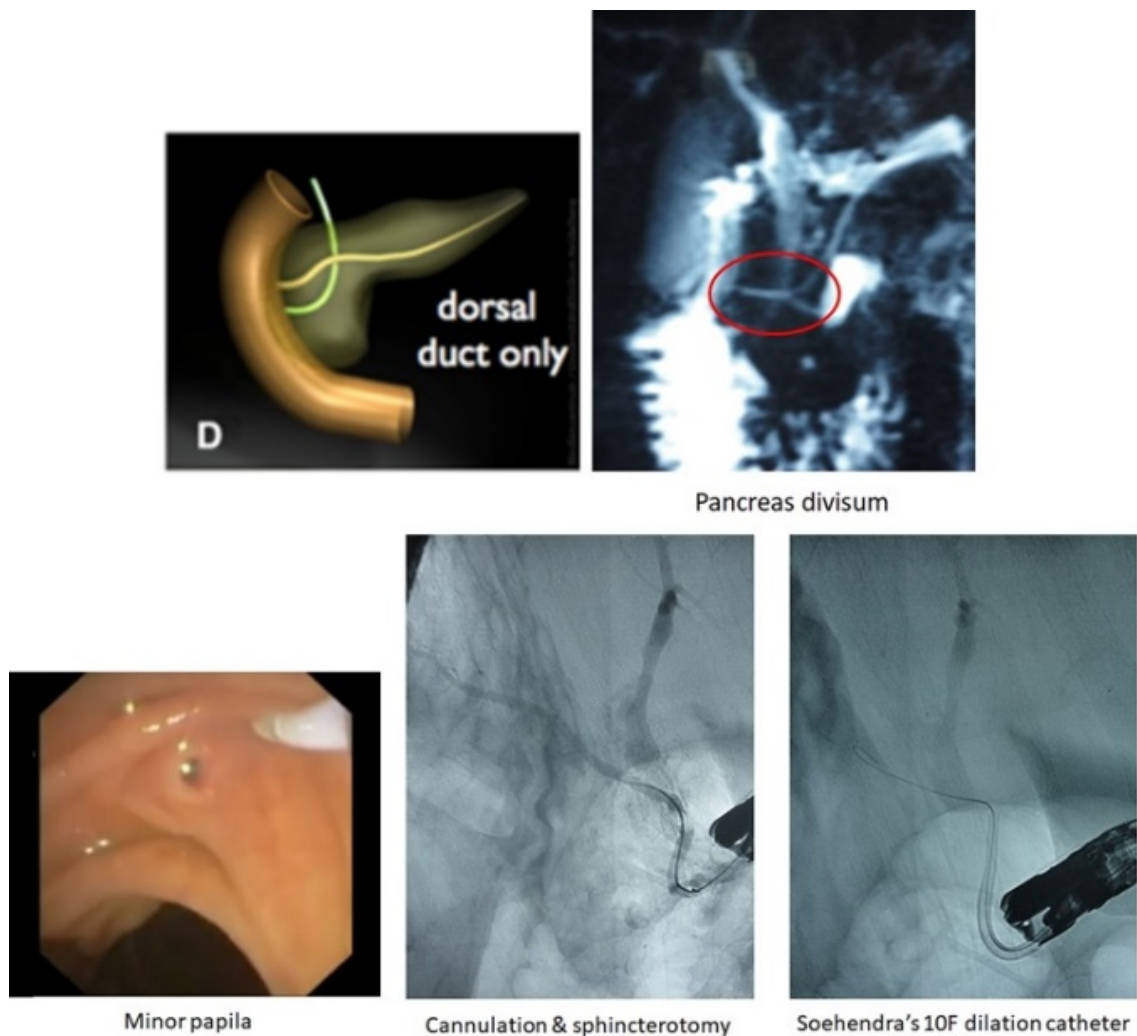
## CASE ILLUSTRATION

A 39 years old male presents with abdominal pain referred by a secondary healthcare facility. He had been diagnosed with pancreatitis twice within the last 1 year prior to his current admission and has undergone magnetic resonance

cholangiopancreatography (MRCP) and endoscopic retrograde cholangiopancreatography (ERCP). His pancreatic enzymes were almost 3000 IU/mL and imaging findings from ERCP and MRCP (**Figure 1**) demonstrated dilatation of dorsal duct that drains to the minor papilla, suggestive of complete pancreas divisum, which unfortunately was not diagnosed by doctors in the secondary healthcare facility. ERCP was done, showing a stenosis in the minor papilla. Treatment is directed towards relieving outflow obstruction at the level of the minor papilla by sphincterotomy and dilation using Soehendra's dilator catheter with successful results. After several days of follow up, his condition improved, the pancreatic enzymes were back to normal levels and the patient was discharged from the hospital without abdominal pain.

## DISCUSSION

Pancreatic divisum is a congenital anatomical anomaly of the pancreas that occurs during the seventh-eighth week of fetal development. Normally, the dorsal pancreatic section will join the ventral pancreatic section to form the main pancreatic duct, then merging with the common bile duct at the hepatopancreatic ampulla and drain into the major duodenal papilla. In this case, we found that the dorsal duct mainly drains to the minor papilla and there is no sign of ventral duct or remnant communication. This type of pancreas divisum (Type II) comprise about 34.4%-37% of pancreas divisum cases. The most common type is the classic pancreas divisum (Type I) which identified in 44.4%-47.8% of pancreas divisum cases.<sup>4,5</sup>



**Figure 1.** MRCP and ERCP images.

Stenosis at the minor papilla in this patient may cause recurrent pancreatitis. In general case of pancreas divisum, they are commonly asymptomatic. Acute pancreatitis is defined as presence of two out of three criterion: abdominal pain, elevated pancreatic enzyme level, and sign of inflammation from imaging.<sup>6</sup> A study reported cases of pancreas divisum were more associated with acute recurrent pancreatitis, found in 55.26% patients, compared to acute and chronic pancreatitis.<sup>7</sup> Another study also showed evidence that a case of pancreas divisum with recurrent pancreatitis could progress to chronic pancreatitis, which can be identified by calcification findings on imaging.<sup>6</sup> In this case, the patient only presented with sign of recurrent acute pancreatitis with no other significant findings.

Definitive diagnosis is made with either ERCP or MRCP. In routine settings, ERCP is considered to be reliable modality to diagnose pancreas divisum. However, ERCP is an invasive procedure which has higher possibility of complication. MRCP is a less invasive procedure which can evaluate biliary and pancreatic duct by actual visualization. S-MRCP is an advanced method by adding secretin to increasing ductal volume and secretion from exocrine pancreas in addition to improving the visualization. S-MRCP has been reported have better specificity in diagnosing pancreas divisum compares to MRCP. The specificity and sensitivity between ERCP and S-MRCP have been shown to have no significant difference in diagnosing pancreas divisum. Although ERCP still remains as gold standard for diagnostic tools in pancreas divisum, MRCP can be used as an alternative for patient who cannot undergo ERCP.<sup>7,8</sup>

The aim of the treatment in this case is to increase pancreas drainage through minor papilla by removing the obstruction. The option of treatment for symptomatic pancreatic divisum is a sphincterotomy of the minor duodenal papilla with or without dilatation. Studies show the successful rate of endotherapy reported more than 70%.<sup>9-11</sup> A study shows the response rate for all patient who underwent endoscopic intervention with pancreatitis symptom was 75.8%.<sup>11</sup> Specifically, patient with acute

recurrent pancreatitis has better response rate compared to patient with chronic pancreatitis.<sup>10,11</sup> Intraprocedural bleeding only occurred in 4.8% patients and none of them required blood transfusion.<sup>11</sup> Successful treatment on this patient was reported with improved clinical condition and no sign of complication.

## CONCLUSION

Patient with acute recurrent pancreatitis or chronic pancreatitis should be considered for further examination to eliminate the possibilities of congenital anomaly. MRCP and ERCP have been proven as reliable diagnostic tools to diagnose pancreas divisum. Management of this case can be performed by endoscopic intervention with promising response rate and minimal risk of complication. This is the first pancreas divisum case reported and successfully treated in Indonesia.

## REFERENCES

1. Kuzel AR, Lodhi MU, Rahim M. Pancreatic divisum: an unusual cause of chronic pancreatitis in a young patient. *Cureus*. Cureus Inc. 2017;9(11):e1856.
2. Liao Z, Gao R, Wang W, et al. A systematic review on endoscopic detection rate, endotherapy, and surgery for pancreas divisum. *Endoscopy*. 2009;41(05):439–44.
3. Türkvtan A, Erden A, Türkoğlu MA, et al. Congenital variants and anomalies of the pancreas and pancreatic duct: imaging by magnetic resonance cholangiopancreatography and multidetector computed tomography. *Korean J Radiol*. Korean Soc Radiol. 2013;14(6):905–13.
4. Adibelli ZH, Adatepe M, Imamoglu C, et al. Anatomic variations of the pancreatic duct and their relevance with the Cambridge classification system: MRCP findings of 1158 consecutive patients. *Radiol Oncol*. De Gruyter Open. 2016;50(4):370–7.
5. Adibelli ZH, Adatepe M, Isayeva L, et al. Pancreas divisum: A risk factor for pancreaticobiliary tumors – an analysis of 1628 MR cholangiography examinations. *Diagn Interv Imaging*. Elsevier Masson. 2017;98(2):141–7.
6. Kuzel AR, Lodhi MU, Rahim M. Pancreatic Divisum: An Unusual Cause of Chronic Pancreatitis in a Young Patient. *Cureus*. Cureus Inc. 2017;9(11):e1856.
7. Wang D-B, Yu J, Fulcher AS, et al. Pancreatitis in patients with pancreas divisum: imaging features at MRI and MRCP. *World J Gastroenterol*. Baishideng Publishing Group Inc. 2013;19(30):4907–16.
8. Mosler P, Akisik F, Sandrasegaran K, et al. Accuracy

- of magnetic resonance cholangiopancreatography in the diagnosis of pancreas divisum. *Dig Dis Sci.* 2012;57(1):170–4.
9. Mariani A, Di Leo M, Petrone MC, et al. Outcome of endotherapy for pancreas divisum in patients with acute recurrent pancreatitis. *World J Gastroenterol.* 2014;20(46):17468.
  10. Kanth R, Samji NS, Inaganti A, et al. Endotherapy in symptomatic pancreas divisum: A systematic review. *Pancreatology.* Elsevier. 2014;14(4):244–50.
  11. Rustagi T, Golioto M. Diagnosis and therapy of pancreas divisum by ERCP: A single center experience. *J Dig Dis.* John Wiley & Sons, Ltd. 2013;14(2):93–9.