

Giant Scrotal Hydrocele and Bilateral Leg Lymphedema as Clinical Manifestation of Chronic Lymphatic Filariasis

Indra Wijaya, Winfrey Pangestu

Department of Internal Medicine, Faculty of Medicine University of Pelita Harapan - Siloam Hospital Lippo Village, Banten, Indonesia.

Corresponding Author:

Indra Wijaya, MD, MSc. Department of Internal Medicine, Faculty of Medicine, Universitas Pelita Harapan - Siloam Hospital Lippo Village. Jl. Boulevard Palem Raya, Lippo Village, Banten 15811, Indonesia. email: indra.wijaya@uph.edu.

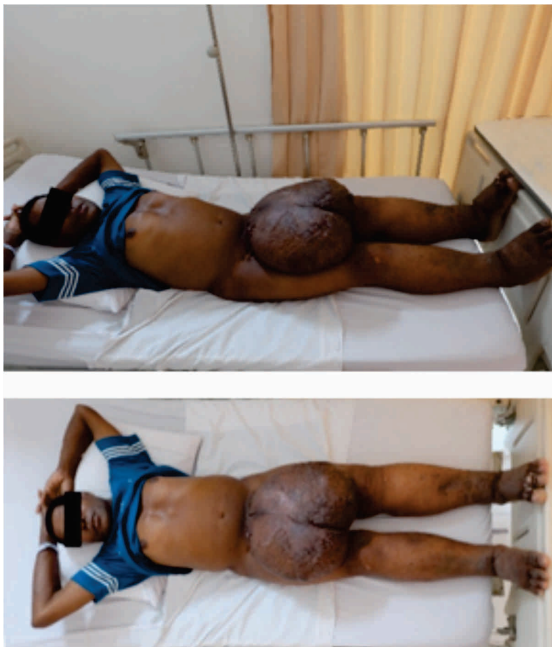

Figure 1. Lying position

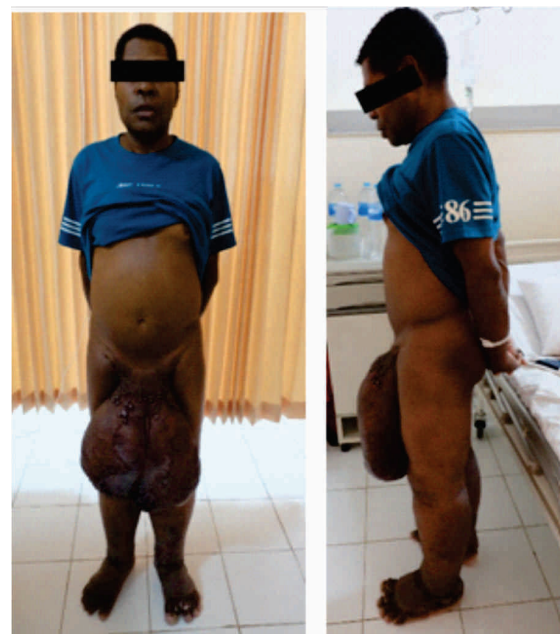

Figure 2. Standing position

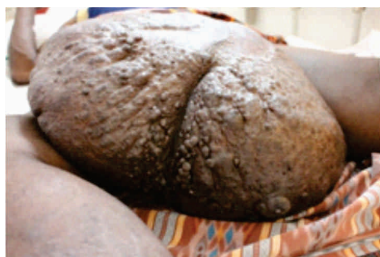

Figure 3. Giant hydrocele

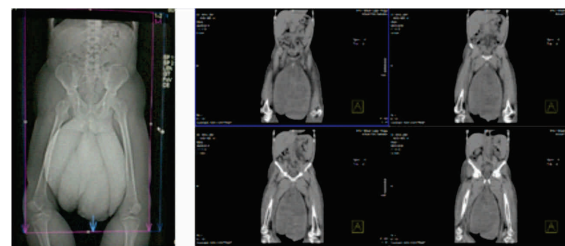


Figure 4. Dual source computed topography scan

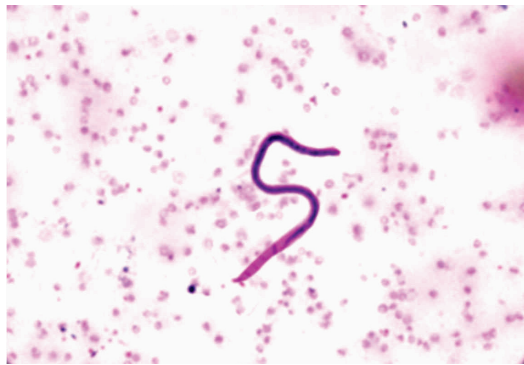

Figure 5. Giemsa staining of sheathed microfilaria *Wuchereria bancrofti* with the tail end does not contain any nuclei

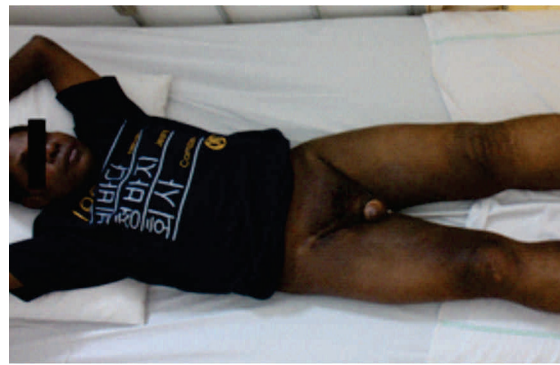

Figure 6. Post Operation

Lymphatic filariasis, commonly known as elephantiasis, is a neglected tropical disease. It is most commonly caused by *Wuchereria bancrofti*, accounting for 90% of all cases. Other causative agents are *Brugia malayi* and *Brugia timori*. Infection occurs when filarial parasites are transmitted to humans through mosquitoes. Infection is usually acquired in childhood causing hidden damage to the lymphatic system leading to the second leading cause of permanent and long-term disability after leprosy. These patients are not only physically disabled, but also suffer mental, social and financial losses contributing to stigma and poverty. Indonesia is one of the ten most endemic country for lymphatic filariasis.¹ It is uncommon for a patient with such giant scrotal elephantiasis to come to health care professionals even in endemic region for filariasis.² This is an interesting case to learn about lymphatic filariasis as a differential diagnosis for genital swelling mainly scrotal tumor and incarcerated herniation.

A 51-year-old male came with the complaint of recurrent swelling in the scrotum and legs. Swelling of the scrotum first appeared 17 years ago in the left scrotum approximately the same size as an apple and underwent surgery. However, 2 years after surgery, the swelling reemerged and gradually increase in size in both scrotums. Left leg swelling began to emerge 5 years ago followed by right leg 3 years after. The patient lives in Sarmi regency Papua province (endemic).

From the physical examination, the patient was afebrile with stage 2 hypertension, pallor conjunctiva, bilateral inguinal lymphadenopathy,

bilateral leg swelling, and hypertrophied, pendulous bilateral scrotal hanging down with complete buried penis (Figure 1). On standing position swelling was hanging up to mid leg with 40 cm x 39 cm x 12 cm in size and multiple wart like protuberances in suprapubic area (Figure 2). There were shallow skin folds in both legs and rounded small knobs clustered together in the left foot mainly the toes, giving rise to peculiar appearance of “mossy foot”. Overlying skin was hard and thickened with slight pain on pressure and non-pitting edema. Other organs revealed in normal condition from physical examination.

From laboratory examination there was microcytic hypochromic anemia with haemoglobin of 7.6 g/dL, low serum iron (17 µg/dL) and low TIBC (101 µg/dL), suggesting anemia of chronic disease. Other results showed reduction of kidney function with eGFR 35.2 mL/minute/1.73 m², ureum 52 mg/dL, creatinine 2.12 mg/dL, high uric acid 10.30 mg/dL, proteinuria 2+/100 mg and hypoalbuminemia (2.57 g/dL). Complete abdominal ultrasound showed bilateral chronic kidney disease and splenomegaly. Chest X-ray showed CTR 55% with elongation and calcification of aorta. The investigation was continued with detection of filarial antigen and Dual Source CT whole abdomen. Midnight blood smear result was positive for microfilaria (Figure 3) which has a sheath and the tail end does not contain any nuclei suggestive of *W. bancrofti*. DS-CT whole abdomen non contrast revealed large septated fluid in bilateral scrotum +/- 25.68 x 34.5 x 36.8 cm, not clearly visible testicular

structure inside suggestive filarial hydrocele and bilateral multiple inguinal lymphadenopathy with diameter +/- 1.82-3.07 cm, paraaortic +/- 0.94-1.26 cm, and parailiac +/- 0.62 cm (Figure 4). Our patient has been given oral albendazole 400 mg single dose, diethylcarbamazine (DEC) 3x200 mg, Captopril 3x12.5 mg, sodium bicarbonate 3x1 gr, folic acid 1x15 mg, vitamin B12 3x1, and iron sucrose injection 2 ampoules 3 times a week, and the patient undergo scrotal reconstruction surgery.

ACKNOWLEDGMENTS

The author reported no conflict of interest and no funding has been received on this work.

REFERENCES

1. World Health Organization (WHO). Lymphatic filariasis fact sheet. Updated February 2016. Available at : www.who.int/mediacentre/factsheets/fs102/en/. Accessed on 23 May 2016.
2. Thejeswi P, Prabhu S. Giant scrotal lymphoedema case report. *Int J Surg Case Rep*. 2012;3(7):269.