

Acquired Hemophilia A Associated with NSAID: A Case Report

Diane L. Setiawan, Yetti Hernaningsih

Department of Clinical Pathology, Faculty of Medicine Universitas Airlangga - Dr. Soetomo Teaching Hospital, Surabaya, Indonesia.

Corresponding Author:

Diane Lukito Setiawan, MD. Department of Clinical Pathology, Faculty of Medicine Universitas Airlangga-Dr. Soetomo Teaching Hospital. Jl. Prof. Dr. Moestopo 6-8, Surabaya, Indonesia. email: diane.lukito.dr@gmail.com.

ABSTRAK

Acquired hemophilia A (AHA) adalah sebuah kelainan pembekuan darah yang disebabkan adanya autoantibodi (inhibitor) terhadap faktor VIII. Gejala yang khas adalah perdarahan bawah kulit dan jaringan lunak (jarang pada sendi), tanpa ada riwayat keluarga maupun riwayat perdarahan sebelumnya. Wanita, 39 tahun, lebam di kedua lengan bawah hilang timbul selama 2 bulan tanpa riwayat trauma. Riwayat konsumsi obat nyeri kepala sejak SMP. Pemeriksaan faal hemostasis didapatkan pemanjangan activated partial tromboplastin test (APTT) 87,1 (24,4-44,4detik) dan rendahnya kadar faktor VIII 5%(60-150%). Pemberian rekombinan faktor VIII membuat kadar faktor VIII menjadi semakin turun (2%). Titer inhibitor faktor VIII 21,12 Bethesda unit sehingga pasien didiagnosis AHA. Penyebab AHA pada penderita ini kemungkinan adalah penggunaan non-steroid anti-inflammatory drug (NSAID) jangka lama. Kasus ini merupakan kasus yang masih jarang ditemukan di Indonesia sehingga tata cara diagnosis dan terapinya masih kurang. Terapi yang tidak tepat dapat menyebabkan kadar faktor VIII semakin menurun.

Kata kunci: *acquired hemophilia, non-steroid anti-inflammatory drug (NSAID), inhibitor, faktor VIII.*

ABSTRACT

Acquired hemophilia A (AHA) is a blood clotting disorder caused by the presence of autoantibodies (inhibitors) against factor VIII. The typical symptom of this disorder is bleeding under the skin and soft tissue (rarely in the joints), with no family or personal previous history of bleeding. This case reports is tended to build up awareness for better diagnosis and therapy. Woman, 39 years old, bruises on both forearms are intermittent for 2 months with a history of long term drug consumption for headache treatment. Hemostatic test showed the elongation of activated partial thromboplastin test (APTT) to 87.1 (normal 24.4-44.4 seconds) and the decreament of factor VIII (FVIII) activity to 5% (normal 60-150%). Provision of recombinant factor VIII lowered factor VIII activity to 2%. Factor VIII inhibitor titer was 21.12 BU and diagnosis AHA was made. Inhibitor eradication by methylprednisolone tablet 3x16mg which was given for 2 months, improved the APPT to 46.7 seconds and factor VIII activity to 36%. Acquired Hemophilia A should be suspected in an adult bleeding patient with history of taking a long time non-steroidal anti-inflammatory drugs (NSAIDs). This case is a rare case in Indonesia and therefore the procedure for diagnosis needs to be improved in order to avoid errors in delivering a therapy which can cause the decreament of factor VIII activity.

Keywords: *acquired hemophilia, non-steroid anti-inflammatory drug (NSAID), inhibitor, faktor VIII.*

INTRODUCTION

Acquired hemophilia A (AHA) is a blood clotting disorder caused by the presence of autoantibodies that interfere with the function of factor VIII, or often called factor VIII inhibitor.¹ This disorder is less common than congenital hemophilia, but it is more life threatening. Its prevalence is similar in men and women i.e. 0.28 /million/year at age <65 years old, rising to 5.97/million/year for 65-85 years old, up to 16.6/million/year for those aged > 85 years old.² Acquired hemophilia A is usually associated with autoimmune diseases, malignancies, skin disorders, drug interactions, and the period after childbirth; even 50% of cases has unknown causes (idiopathic).³⁻⁵

Acquired hemophilia A was often misdiagnosed as another blood clotting disorder. Its bleeding manifestation was different from the congenital hemophilia. The bleeding often occurs under the skin (purpura/ecchymosis) and soft tissue, and rarely found in the joints (hemarthroses).^{2,6} The presence of factor VIII inhibitor causes a disruption in the intrinsic coagulation pathway, causing elongation of the activated partial thromboplastin time (APTT) parameter which did not show improvement after mixing test and it has low activity of factor VIII.³

Management of patients with AHA aims to overcome the bleeding and its complications, as well as the eradication of the factor VIII inhibitors. Eradication of the inhibitor with immunosuppressive therapy usually begins with corticosteroids such as prednisolone 1 mg/kg/day. The treatment is continued for 3 months, while patient's response to therapy is being monitored.⁶⁻⁸

This case report is intended to build up awareness for better diagnosis and therapy. This article highlights a case of an adult woman, with a history of long term NSAIDs consumption for headache treatment, that experience a history of spontaneous bleeding under the skin for one and a half months. She finally was being diagnosed with AHA.

CASE ILLUSTRATION

A 39-year-old woman went to the doctor on December 2015 with complaints of intermittently

spontaneous bruises on both arms since the beginning of November 2015, with no tenderness found on the bruises. A history of trauma was denied by the patient. She also reported minor bleeding gums when she brushed her teeth. There were no bruises on the joints and a history of nosebleeds or unstoppable bleeding due to injuries was denied. The menstrual cycle of the patient was normal and the drastic weight loss in recent months was denied as well.

The patient had a history of regular frequent intake of a drug which contains acetosal, paracetamol, and caffeine, for headache treatment since she was in junior high school. She had consulted several times with a neurologist and then was diagnosed as migraine. A few years ago, she had a head CT Scanning with normal result. The patient is the first child of 3 siblings and married with two children who were born normally with no history of bleeding prior to, during, and after childbirth. The youngest child of the patient is 10 years old.

The patient's general state looked healthy, weight 52 kg, with the vital signs of blood pressure 120/70 mm Hg, pulse rate 84 beats/min, respiratory rate 20 times/min, and temperature of 37°C. Head and neck had a little anemia, without jaundice, cyanosis, and dyspnea. The thoracic examination indicated symmetrical movements, no retraction, normal sound of heart and lungs. Abdomen examination was found flexible, and also normal bowel sound, liver and spleen were not palpable. The extremities examination were found warm, dry, red, but in the region of the right and left forearms, were obtained fairly extensive ecchymosis without tenderness (**Figure 1**).

All laboratory result was shown the initial CBC; normochromic anemia, increment number of platelet, and elongation of APTT with normal plasma prothrombin time (PPT). Liver and kidney function test results were within normal limits and anti-nuclear antibody (ANA) was not detected. The patient was referred to a hematologist and medical oncologist consultant who gave her a referral to conduct laboratory examinations. The test results showed very low activity of factor VIII with normal von Willebrand factor and fibrinogen level. The

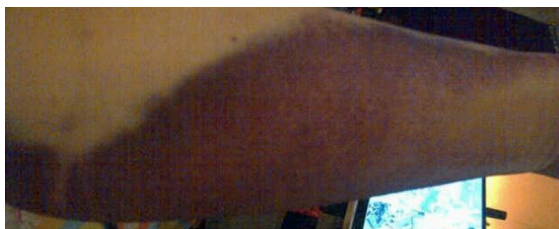

Figure 1. Ecchymosis on left forearm.

patient was hospitalized on December 22nd, 2015 for three days and was treated with recombinant factor VIII 1500 IU/day. The next examination (December 28th, 2015) showed that factor VIII activity decreased after recombinant factor VIII therapy despite the diminishing symptoms of ecchymosis (**Figure 2**).

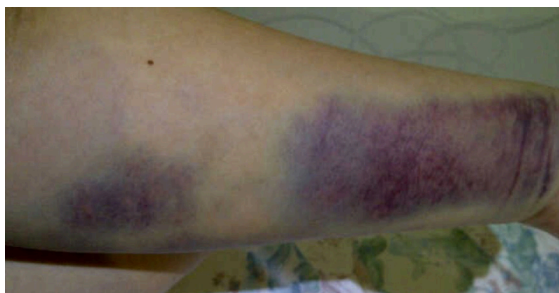

Figure 2. Ecchymosis on left forearm after recombinant factor VIII therapy.

Examination of factor VIII, factor IX activity and inhibitor of factor VIII done in January 4th, 2016 revealed that factor VIII activity was low, whereas factor IX activity was normal. The examination of factor VIII inhibitor level using the Bethesda titer showed a high level at 21.12 BU (Bethesda Units). Examination of circulating anticoagulant—which is a modification method from Bethesda titer—showed that the inhibitor concentration is still high despite the patient's factor VIII activity has increased. One part of the patient plasma which was mixed with nine parts of control plasma, have not produced normal APTT value yet.

Therapy of methylprednisolone 3x16 mg/day for two weeks could diminish the inhibitor of factor VIII. Examination after two weeks of therapy showed an increase in factor VIII activity; the methylprednisolone was being tapered-off until third month of therapy. Factor

VIII activity was increasing at the end of the second month of treatment. The inhibitor was not detected in the end of therapy.

DISCUSSION

Hemophilia A is a bleeding disorder caused by disturbances in factor VIII. This disorder can be present at birth (congenital) due to mutations in genes forming factor VIII or may appear in adulthood (acquired). Gene mutation which shapes congenital factor VIII in hemophilia is inherited because it is linked to the X chromosome (X-linked inherited), so that this disorder is mostly suffered by men.^{1,7} Acquired Hemophilia A (AHA) is a rare case in which the body produces autoantibodies (usually IgG) against factor VIII.⁸ The disorder is not inherited so that men and women have similar prevalence to suffer AHA.^{1,9,10}

Factor VIII activity in patients with AHA is not comparable with the arise symptoms of bleeding, unlike congenital hemophilia patients who show the severity of bleeding related to the activity of factor VIII.^{2,6} This case showed an adult female patient who was eventually diagnosed with AHA. AHA diagnosis in this patient was based on her clinical symptoms of bleeding under the skin which emerge when the patient has grown up as an adult, with no previous personal history of bleeding or a history of bleeding in the family. Anemia that was shown from decreased levels of hemoglobin and hematocrit of the patient showed that the bleeding happens quite a lot. The differential diagnosis of this patient was another blood clotting factor deficiency, lupus anticoagulant, and von Willebrand disease (vWD). The activity of factor IX and von Willebrand factor showed normal results, while symptoms of lupus anticoagulant led to thrombosis rather than haemorrhage.

Causes of AHA 50% is unknown (idiopathic), 20% are due to an autoimmune disease, 10% as a result of pregnancy, while the rest is due to malignancy or interactions with drugs such as antibiotics, non-steroidal anti-inflammatory drugs (NSAIDs) and aspirin, anticonvulsant, or anti hypertension.^{9,10} The clinical symptoms of the patient did not show any autoimmune disease,

supported by negative ANA result; so that the cause of AHA in this patient may be caused by anti-drug interaction or idiopathic headache. Patient was also not in a pregnant condition or had just given birth so that the possible cause of AHA is the long term consumption of anti-headache drug (NSAID).

The elongation of APTT value and low activity of factor VIII showed that the patient experienced hemophilia A. The cause of APTT elongation should be determined by conducting a mixing test in advance, i.e. 1 part of patient plasma is mixed with 1 part of normal plasma, and then the value of its APTT is subsequently re-measured.⁹ The result of APTT after mixing test which was not corrected is 50% (24/3/16: Mixing test 1:1 APTT=39.6 seconds); it indicates that the value of APTT elongation caused by the inhibitor is not due to deficiency of factor VIII.

Factor VIII inhibitor was confirmed by checking the levels of inhibitor using the Bethesda method. The inhibitors in patients with AHA is an autoantibody that is dependent on time and temperature, so that incubation of patient plasma with normal plasma was done for 2 hours at 37°C.^{7,9,10} The examination produced a high titer inhibitor (21.12 BU). Type 1 inhibitor (first-order kinetics) can usually be formed in 20-40% of patients with congenital hemophilia A as a result of treatment with recombinant factor VIII (aloantibody); whereas inhibitor in patients with AHA is a type 2 inhibitor. Type 1 inhibitor showed the complete inactivation of factor VIII in accordance with the time of incubation, whereas type 2 inhibitor showed inactivation of factor VIII that formed the plateau graph (Figure 3).⁷

At a glance, this experiment figures are similar to those of APTT examination of the patient's blood samples. The patient's APTT value at initial examination was 46.1 seconds. A mixing test with normal plasma in the "hour 0" (t=0) generated APTT value of 27.9 seconds. APTT value after one hour incubation with normal plasma was 30.3 seconds, after two hours incubation with normal plasma was 36.5 seconds, and after three hours incubation, the APTT value was 36.5 seconds (Figure 4). Figures of inhibitor types were visible at the second and third hour

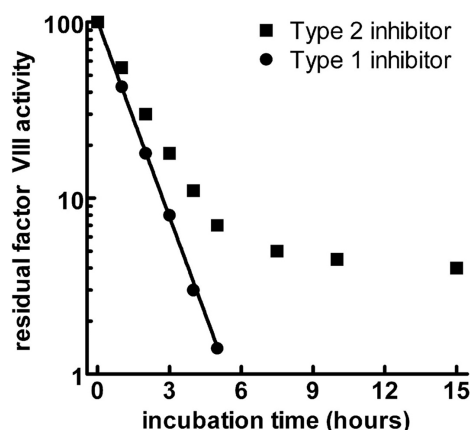


Figure 3. Activity of type 1 and type 2 inhibitor on factor VIII⁷

of examination.

The principle of AHA patient therapy is aimed at stopping bleeding and eradicating the inhibitors. Provision of recombinant factor VIII is not recommended in patients with factor VIII inhibitor levels >5 BU (Bethesda Units), as it would further increase its inhibitor level.^{7,12,13} Bypassing agent therapy such as active recombinant factor VII has shown good results in stopping the bleeding; while to eradicate inhibitors, it commonly uses immunosuppressive drugs such as corticosteroids, cytotoxic agents (cyclophosphamide, cyclosporine), and rituximab (monoclonal antibody anti CD-20).^{2,9,11} Monitoring of therapy can be done by checking factor VIII activity and factor VIII inhibitor which are done regularly (after 7-8 weeks of therapy).^{9,14,15} Patients in this case showed a good response to oral corticosteroids (methylprednisolone) with a single dose of 1 mg/kg/day. Factor VIII activity at the end of

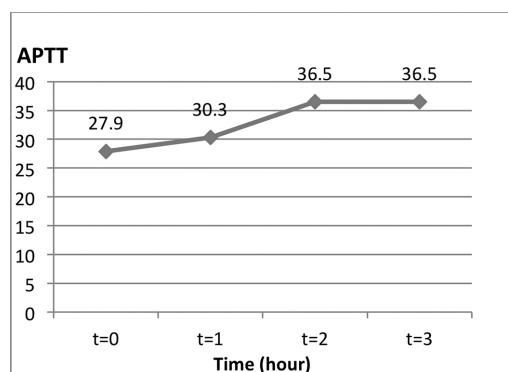


Figure 4. The APTT graph with incubation time of patient plasma:normal plasma (1:1).

the second month of therapy increased to 36%. Methylprednisolone dose was then lowered gradually and the drug was stopped on the third month of therapy. Inhibitor was undetectable and the examination of factor VIII activity showed 43% (normal) at the end of the fifth month.

CONCLUSION

Acquired Hemophilia A is rare so that the procedures for the diagnosis and treatment are still very limited. The patient was diagnosed with AHA because bleeding symptoms under the skin appeared in adult age with no prior history of bleeding. Test results show an elongation of APTT value, low activity of factor VIII, and high level of factor VIII inhibitor. The possible cause of AHA in this patient is the long term consumption of NSAIDs. Single steroid therapy per oral and discontinuation of NSAIDs was found to eradicate the inhibitor of factor VIII in the patient's body. The procedure for AHA diagnosis needs to be improved in order to avoid errors in delivering a therapy which can cause the decreament of factor VIII activity.

ACKNOWLEDGMENTS

The authors stated that they had no interests which might be perceived as posing a conflict or bias.

REFERENCES

1. Flisinski M, Windyga J, Stefariska E, et al. Acquired hemophilia: a case report. *Polskie Archiwum Medycyny Wewnetrznej*. 2008;118(4).
2. Tirunagari S, Shaik D. Hemophilia & Acquired Hemophilia A. *Webmed Central CLINICAL TRIALS* 2013;4(3):WMC004048.
3. Stefanacci RG. Acquired inhibitors: A special case of bleeding in older adults. *Curr Gerontol Geriatric Res*. 2012;308109:5. doi:10.1155/2012/308109.
4. Shah G, Kandra A, Drelich D. Acquired hemophilia A: A case report. *Med Forum*. 2011;11:7.
5. Freire M, Teodoro RB, Nogueira DA, et al. Acquired hemophilia associated with rheumatoid arthritis. *Bras J Rheumatol*. 2009;49(3):302-7.
6. Giangrande P. Acquired hemophilia. Revised edition. *Treatment of hemophilia*. World Fed Hemophilia. 2012:38.
7. Ma AD, Carrizosa D. Acquired factor VIII inhibitors: Pathophysiology and treatment. *Am Soc Hematol*. 2006:432-7.
8. Lee JJ, Chung IJ, Park MR, et al. Acquired hemophilia successfully treated with oral immunosuppressive therapy. *Korean J Intern Med*. 2000;15:2.
9. Collins P, Baudo F, Huth-Kuhne A, et al. Consensus recommendation for the diagnosis and treatment of acquired hemophilia A. *BMC Res Notes*. 2010;3:161.
10. Sakurai Y, Takeda T. Acquired hemophilia A: A frequently overlooked autoimmune hemorrhagic disorder. *J Immunol Res*. 2014;320674.
11. Tufano A, Coppola A, Guida A. Acquired hemophilia A in the elderly: Case reports. *Curr Gerontol Geriatric Res*. 2010;927503.
12. Pathirana UGP, Gunawardena N, Abeyasinghe H, et al. Acquired hemophilia A associated with autoimmune thyroiditis: A case report. *J Med Case Reports*. 2014;8:469.
13. Orlova NA, Kovnin I, Vorobiev I. Blood clotting factor VIII: From evolution to therapy. *Acta Naturae*. 2013;5(17):2013.
14. Tanaka TN, Sohda S, Someya K. Acquired hemophilia due to factor VIII inhibitors in ovarian hyperstimulation syndrome: Case report. *Human Reproduction*. 2003;18(3):506-8.
15. Murray NP, Moncada JC, Moran M. Duodenal tumor presenting as acquired hemophilia in an 88-year-old woman: A clinical case and review of literature. *Case Reports in Gastrointestinal Medicine*. 2012;203801.