Uncorrected Tetralogy of Fallot Complicated by Brain Abscess and Postoperative Intracranial Haemorrhage: A Case Report

Fanny Puspita Haryono[1], Agnes Lucia Panda[2], Ventje Ramond Kawengian[3]

[1]Resident of Internal Medicine, Faculty of Medicine, Sam Ratulangi University, Manado, Indonesia.
[2]Department of Cardiovascular Medicine, Prof. R.D. Kandou General Hospital, North Sulawesi, Manado, Indonesia.
[3]Department of Psychosomatic Medicine, Prof. R.D. Kandou General Hospital, North Sulawesi, Manado, Indonesia.

Corresponding Author:
Fanny Puspita Haryono, MD. Department of Internal Medicine, Faculty of Medicine, Sam Ratulangi University. Jl. Raya Tanawangko No. 56, Malalayang, Manado 95115, Indonesia. Email: fan89wk07@gmail.com

ABSTRACT

Cerebral abscess is a rare but potentially fatal complication of cyanotic congenital heart disease, in which chronic hypoxia, polycythaemia and right-to-left shunting allow bacteraemia to bypass pulmonary filtration. A woman in her 20s with uncorrected tetralogy of Fallot presented with severe headache, right-sided weakness and seizures. Examination showed hemiparesis, hypoaesthesia and hyperreflexia; blood tests revealed secondary polycythaemia and leucocytosis. No dental, sinus, otological or respiratory source was identified. Unenhanced computed tomography demonstrated a left parietal space-occupying lesion with midline shift, and echocardiography confirmed tetralogy of Fallot with pulmonary atresia. She received ceftriaxone, metronidazole and dexamethasone, followed by burr-hole drainage. Recovery was complicated by epidural haemorrhage requiring emergency craniotomy and a later subdural haematoma with focal seizures, both managed successfully. This case illustrates that new focal neurological signs in uncorrected cyanotic heart disease warrant urgent imaging for brain abscess, and that polycythaemia compounds perioperative haemorrhagic risk.

Keywords: *Tetralogy of fallot, brain abscess, hematoma subdural, hematoma epidural, cranial, polycythemia, drainage.*

INTRODUCTION

A brain abscess is a localized intracranial infection that begins as cerebritis and progresses into a collection of pus surrounded by a well-formed capsule. Brain abscesses may be caused by various microorganisms, including bacteria, fungi, and parasites, originating either from contiguous infectious foci adjacent to the brain or through hematogenous spread.[1] In the United States, the annual incidence of brain abscess is estimated at 1,500–2,500 cases. The incidence is higher in developing countries, where approximately 25% of cases occur in children.[1]

A study conducted in South Africa reported 973 cases of brain abscess, with a mean patient age of 24 years. Of these patients, 75% were male; 39% of cases were of otogenic origin, and 33% were related to trauma.[2] A 2011 study at Cipto Mangunkusumo Hospital identified 11 patients with brain abscesses, showing a higher prevalence in males. Most lesions were located in the supratentorial region, with a mean patient age of 32 years. The majority of cases were associated with chronic ear infections.[3]

Early diagnosis of brain abscess remains challenging due to its nonspecific clinical presentation. Symptoms vary depending on the

size and location of the lesion, as well as the virulence of the causative organism. Neurological deficits resulting from brain abscesses may be permanent, even after appropriate treatment; therefore, prompt diagnostic evaluation is crucial. Supportive imaging studies such as computed tomography (CT) are essential for initial assessment, while magnetic resonance imaging (MRI) is required to confirm the diagnosis and guide appropriate therapeutic management.

Primary risk factors for brain abscess include persistent hypoxia, which leads to polycythemia, hyperviscosity, and impaired host immune function. Brain abscesses in patients with cyanotic congenital heart disease (CHD) are most commonly associated with tetralogy of Fallot (TOF).[4] Tetralogy of Fallot is characterized by four anatomical abnormalities: pulmonary stenosis or right ventricular outflow tract obstruction, ventricular septal defect, overriding aorta, and right ventricular hypertrophy.

TOF is the most common form of cyanotic congenital heart disease and accounts for approximately 10% of all congenital heart defects, with an incidence of about three per 10,000 live births. The presence of cyanotic congenital heart disease significantly increases the risk of brain abscess formation. Although brain complications associated with CCHD are more frequently observed in pediatric patients, they may also occur in adults, where they can substantially impair functional capacity and productivity.[4]

CASE ILLUSTRATION

A 20-year-old woman presented to Prof. Dr. R.D. Kandou General Hospital, Manado, with a chief complaint of decreased level of consciousness. The patient was referred in a stepwise manner from Monompia Hospital. Due to limited resources and facilities, she was subsequently transferred to Hermina Hospital and is currently referred to Prof. Dr. R.D. Kandou General Hospital. The patient had been admitted to Monompia Hospital since October 30, 2025, following a sudden episode of syncope. Before the fainting episode, she complained of headache, which she had experienced intermittently for many years. The headaches first began at the age of 13, typically lasting 5– 10 minutes and shifting in location. However, during the week preceding admission, the headaches became significantly more severe and persistent, predominantly affecting the left side of the head. During this period, the patient also appeared restless and struggling unconsciously. Beginning on November 2, 2025, the patient developed sudden paralysis of the right upper and lower extremities, with both limbs becoming immobile.

Past medical history revealed that since the age of three years, the patient had experienced recurrent episodes of dyspnea, particularly during physical activity, which improved with rest. She also had frequent episodes of perioral cyanosis, sudden startling, generalized weakness, and palpitations. A history of habitual squatting during childhood was denied. The patient had previously been evaluated by a physician and was informed of a congenital heart disorder; however, no regular follow-up or treatment was pursued. Due to her known cardiac condition, she was exempted from participating in sports activities at school. In adolescence, she had a persistent bluish tint to the skin, lips, and nail beds caused by low blood oxygen; she often squats down when short of breath to increase blood flow to the lungs and relieve symptoms. She had rounding and swelling of the tips of fingers and toes (digital clubbing) from long-term low oxygen levels. Physical growth and puberty may be significantly delayed. In 13-15 years, she complains of recurrent headaches; her laboratory investigations revealed a hemoglobin of 15-18 g/dl and hematocrit of 50-55 % suggesting polycythemia. She frequently has fevers, coughs, and colds, more frequently than other children. She also started menstruating at age 18. Her grades at school are lower than those of other children. Her dream is to be a good housewife. She doesn't have the same lofty dreams as her peers.

Before referral, the patient received treatment at Hermina Hospital consisting of citicoline 100 mg once daily, aspirin 100 mg once daily, paracetamol 500 mg every 8 hours, ranitidine 150 mg every 12 hours, and propranolol 10 mg once daily. Upon admission to Prof. Dr. R.D. Kandou General Hospital, she was managed

with intravenous omeprazole 40 mg every 12 hours, ketorolac 30 mg every 8 hours, and ondansetron 4 mg every 8 hours as prescribed by the surgical team. From the cardiology service, she received aspirin (Aspilet®) 100 mg once daily and propranolol 10 mg once daily, with a plan for right heart catheterization once her condition stabilized. Additional therapy included intravenous ceftriaxone 2 g every 12 hours, metronidazole

500 mg every 6 hours by infusion, and dexamethasone with a loading dose of 10 mg intravenously followed by 5 mg every 6 hours, tapered daily, initiated on November 23, 2025, while the patient was treated in the Intensive Respiratory Disease Management unit starting November 22, 2025.

From the neurosurgery service, the patient received intravenous paracetamol 1 g every 8 hours, phenytoin injection 100 mg every 8 hours, close monitoring of consciousness level, and head elevation at 30°. A burr-hole procedure for abscess drainage was planned and performed on December 1, 2025, followed by craniotomy on December 4, 2025.

On physical examination, the patient appeared apathetic, with a Glasgow Coma Scale score of E4V (aphasia) M4 (predominantly left extremity response). Her body weight was 50 kg, height 158 cm, and body mass index was 22.2 kg/m², indicating normal nutritional status. Vital signs revealed hypotension with a blood pressure of 80/54 mmHg without vasopressor support, pulse rate of 88 beats per minute, respiratory rate of 22 breaths per minute, body temperature of 36.7°C, and oxygen saturation of 90% while receiving oxygen via nasal cannula at 3 L/min.

Head examination showed mild perioral cyanosis. Neck examination revealed no jugular venous distension (JVP approximately 5+4 cmH_2O) and no lymphadenopathy. Pulmonary examination demonstrated symmetrical chest expansion, normal vocal fremitus, and vesicular breath sounds without rhonchi or wheezing. Cardiac examination revealed a laterally displaced apical impulse at the fifth intercostal space along the left anterior axillary line. On auscultation, a single second heart sound was noted, accompanied by a systolic ejection murmur best heard at the pulmonary area.

Abdominal examination was unremarkable. Examination of the extremities showed warm acral areas, bilateral pretibial pitting edema, and digital clubbing of all fingers and toes, as shown in **Figure 1**. Neurological examination revealed round, isochoric pupils measuring 3 mm bilaterally, with intact direct and consensual light reflexes. There were no signs of meningeal irritation; neck stiffness was absent, Lasegue test was greater than 70° bilaterally, and Kernig sign was greater than 135° bilaterally. Fundoscopic examination demonstrated papilledema grade II–III. Cranial nerve examination suggested right-sided upper motor neuron facial nerve paresis.

Motor examination revealed right hemiparesis, with muscle strength graded as 0/5 in both the right upper and lower extremities, while the left upper and lower extremities demonstrated normal strength (5/5). Muscle tone was normal on the left side and hypotonic on the right. Deep tendon reflexes were normoreflexive in all four extremities, and pathological reflexes were absent bilaterally. Sensory examination was not assessable at the time of evaluation, although it had previously been normal. Autonomic function was preserved, with no urinary or fecal incontinence.

Given the patient's history of tetralogy of Fallot, an electrocardiographic (ECG) examination was performed. The ECG demonstrated sinus rhythm with a heart rate of 88 beats per minute, normal electrical axis, and features consistent with right ventricular hypertrophy (RVH), as shown in **Figure 2**. Transthoracic echocardiography revealed situs solitus with atrioventricular concordance. Ventriculoarterial discordance was noted in the form of pulmonary atresia. All pulmonary veins drained into the left atrium. Additional findings included right ventricular hypertrophy, an overriding aorta, and a perimembranous ventricular septal defect measuring 13–16 mm, with a bidirectional shunt predominantly from right to left. No atrial septal defect or patent ductus arteriosus was identified. Left ventricular systolic function was preserved, with a left ventricular ejection fraction of 66% (Teichholz method), and right ventricular contractility was normal, with a tricuspid annular plane systolic

excursion (TAPSE) of 1.95 cm. Trivial tricuspid regurgitation was present. The pulmonary valve was non- confluent with pulmonary atresia. Other cardiac valves were within normal limits. The aortic arch was left-sided, with no evidence of coarctation of the aorta. The inferior vena cava measured 1.0 cm in diameter with approximately 50%collapsibility, corresponding to an estimated right atrial pressure of 3 mmHg. Overall, these findings were consistent with pulmonary atresia with ventricular septal defect (PA-VSD), and cardiac catheterization was recommended **Figure 3**.

Routine laboratory investigations showed an elevated hemoglobin level of 17.1 g/dL and a hematocrit of 50.3%, consistent with secondary polycythemia. C-reactive protein was markedly elevated at 48.00 mg/L, suggesting active inflammation or infection. Peripheral blood smear examination revealed erythrocytosis, suspected to be secondary in etiology, with leukocytosis consistent with infection or inflammatory processes.

Urinalysis demonstrated the presence of bacteria and ketones (+2). Cytological examination of the cerebrospinal fluid (CSF) revealed clear, colorless fluid with a volume of approximately 5 mL. No malignant cells were identified. The smear contained 1–2 mature lymphocytes against an amorphous background. Microbiological culture and antibiotic susceptibility testing of the abscess material obtained on December 1, 2025, identified *Staphylococcus hominis*. The organism was sensitive to trimethoprim–sulfamethoxazole and vancomycin, but resistant to erythromycin, clindamycin, oxacillin, and tetracycline.

A posteroanterior (PA) chest radiograph demonstrated normal thoracic skeletal structures. The pulmonary fields and cardiac silhouette were within normal limits **Figure 4**.

R.D. Kandou General Hospital on November 22, 2025, revealed a hypodense lesion with well-defined margins and multiple isodense rims located in the left corona radiata, appearing elliptical in shape and measuring approximately 5.0 × 2.3 cm. An additional round hypodense lesion measuring 1.6 cm in diameter was identified in the left parietal lobe. Both lesions were surrounded by finger-like vasogenic edema extending into the centrum semiovale and the left intraparietal sulcus. These findings resulted in obliteration of the left lateral ventricle and a rightward midline shift of approximately 1.2 cm, consistent with a cerebral abscess. There was also narrowing of the cerebral sulci, suggesting associated cerebral edema **Figure 5**.

On November 25, 2025, after a burr hole operation, she experienced generalized seizures that persisted for two days despite anticonvulsant therapy given. The patient subsequently underwent neurosurgical intervention, after which her symptoms initially improved.

A contrast-enhanced head CT scan performed on November 25, 2025, demonstrated progression of the lesion. A hypodense mass with multiple isodense rims and well-defined borders was observed in the left corona radiata, elliptical in shape, measuring 50.5 × 30.9 mm. The lesion involved the truncus of the corpus callosum,

Figure 1. Cyanosis and clubbing in a patient with congenital heart disease

septum pellucidum, and fornix. Surrounding finger-like edema measuring approximately 19.0 × 9.5 mm extended into the centrum semiovale and precentral and postcentral sulci. These findings caused complete obliteration of the left lateral ventricle and a marked rightward midline shift of approximately 14.9 mm. The overall radiological impression was consistent with a cerebral abscess **Figure 6**.

All acute epidural hematomas occurred adjacent to the burr hole site and were confirmed on immediate postoperative computed tomography (CT) scan. The patient showed decreased levels of consciousness and underwent emergent craniotomy on November 26, 2025, and hematoma evacuation; they recovered with significant neurological deficits.

A non-contrast head computed tomography (CT) scan performed at Prof. Dr. R.D. Kandou General Hospital on December 3, 2025, demonstrated a hyperdense, biconvex lesion in the left temporoparietal region with an estimated volume of 59.6 cc, causing a rightward midline shift of approximately 2.0 cm. Multiple hypodense lesions surrounded by hyperdense areas were observed in the left temporoparietal region, while additional hypodense areas were noted within the bilateral frontal and right frontoparietal cerebral spaces, findings consistent with pneumoencephaly. A hyperdense structure extending through the left parietal calvaria and coursing caudally toward the splenium of the corpus callosum and cerebral aqueduct was identified, consistent with an external ventricular drain (EVD). Bone window images revealed a bone defect at the left vertex and parietal region **Figure 7**.

However, starting on December 3, 2025, the patient developed aphasia; although she was able to open her eyes and demonstrated comprehension of spoken language, she was unable to produce speech. During the same period, she experienced intermittent facial muscle spasms lasting approximately 20–30 seconds, occurring repeatedly over five consecutive days.

A follow-up non-contrast head CT scan performed on December 9, 2025, revealed an elliptical hyperdense lesion in the left parieto-occipital region measuring approximately 1.7 cm in thickness, associated with a rightward midline shift of 1.4 cm, suggestive of a subdural hematoma. Additionally, a hypodense lesion in the left paraventricular region surrounded by finger-like edema was identified, consistent with a residual or recurrent cerebral abscess **Figure 8**.

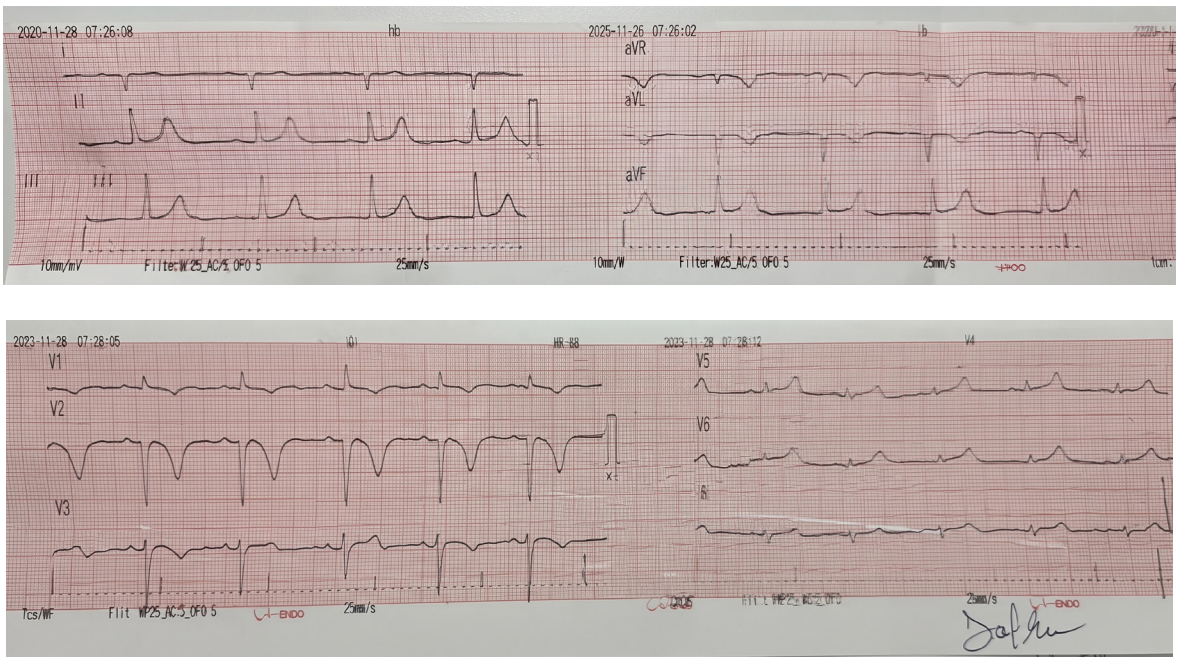

Figure 2. ECG: sinus rhythm, heart rate 88 bpm, normoaxis, RVH.

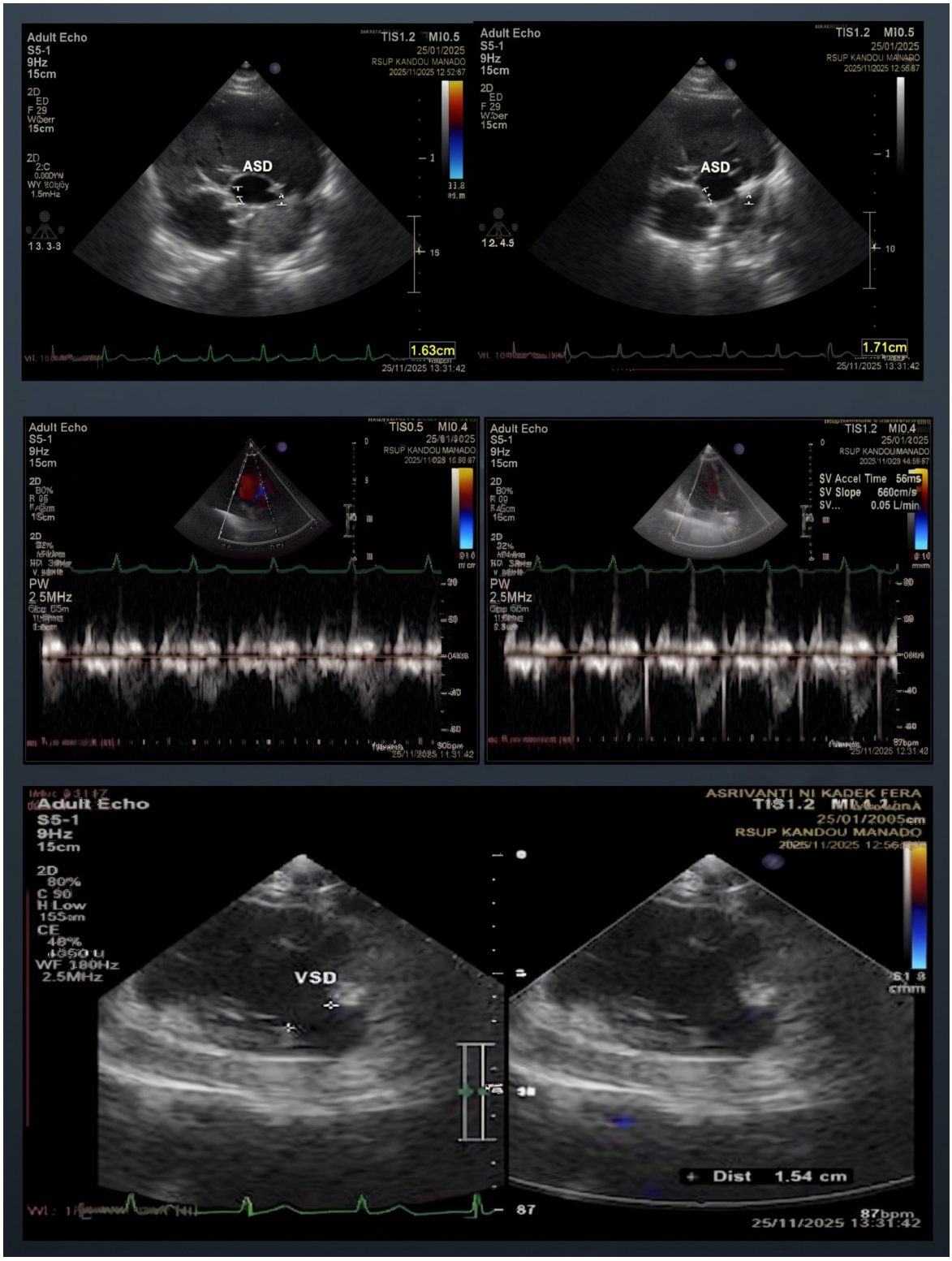

Figure 3. Transthoracic echocardiography

She was managed conservatively but recovered with neurological deficits. The patient with drainage catheters in situ developed acute SDH.

The family was offered a repeat craniotomy, but the family refused. So the patient only received conservative treatment from a neurologist and an internist. Based on the clinical

Figure 4. Posteroanterior chest radiograph.

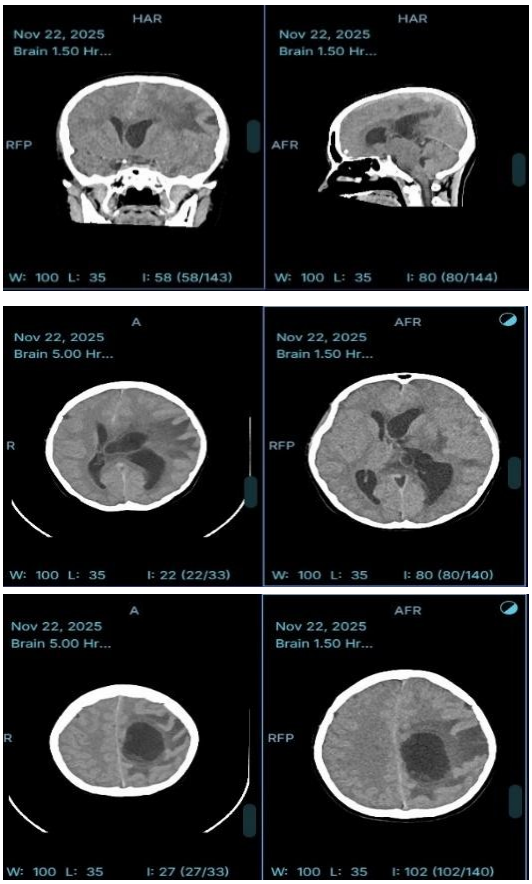

Figure 5. CT scan dated November 22, 2025

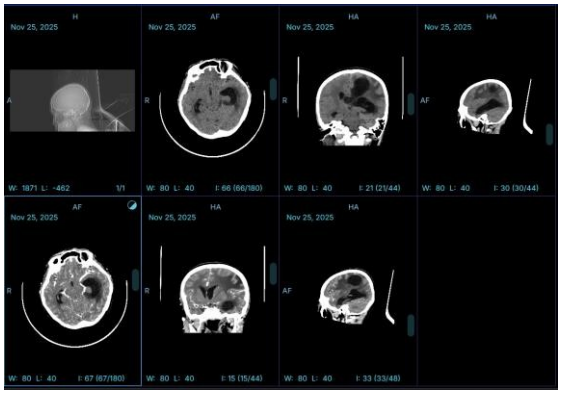

Figure 6. CT scan dated November 25, 2025

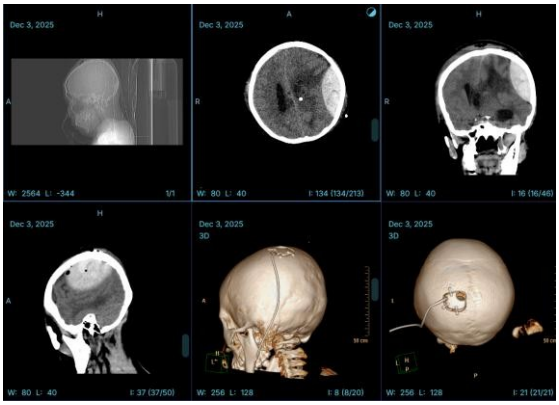

Figure 7. CT scan of the head dated December 3, 2025

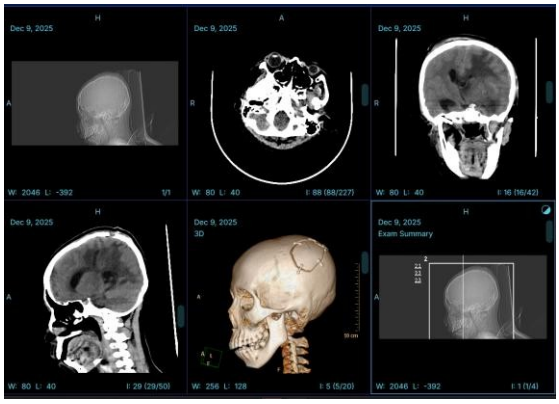

Figure 8. CT scan of the head dated December 9, 2025

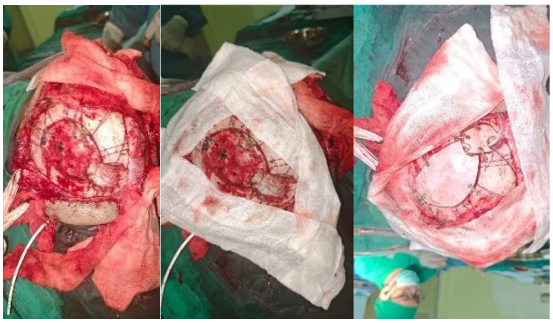

Figure 9. Burr hole and craniotomy

findings, imaging studies, and laboratory results, the patient was diagnosed with adult congenital heart disease, specifically tetralogy of Fallot with pulmonary atresia and ventricular septal defect, secondary polycythemia, left temporoparietal epidural hematoma status post craniotomy and hematoma evacuation, status post burr-hole and craniotomy drainage of a cerebral abscess, left temporo-occipital subdural hematoma, and ventriculomegaly.

The patient received medical management from the neurology service, including levetiracetam 1,000 mg every 12 hours, clobazam 10 mg every 8 hours, and a loading dose of topiramate 300 mg initiated on December 12, 2025, administered for three days, followed by a maintenance dose of 100 mg every 12 hours. Metoclopramide 10 mg every 8 hours was also prescribed.

From the neurosurgery service, the patient was treated with cotrimoxazole 960 mg every 12 hours, with a plan for continued outpatient therapy. Cardiology management included bisoprolol 5 mg once daily, and a right heart catheterization was planned as part of further evaluation once the patient's condition stabilized.

DISCUSSION

Tetralogy of Fallot (TOF) is a congenital heart disease that combines four major developmental defects of the heart. Such defects with an underlying right-to-left-sided shunt present with cyanosis early in childhood and thus are alternatively named as cyanotic heart diseases. Complications of untreated TOF, such as improper growth and development of the child, delayed milestones, secondary polycythemia, and a more severe infective endocarditis, are characteristic; however, a rare albeit serious complication, brain abscess, has also been reported as a presenting complaint [5]. This patient had all the symptoms since the age of 3 years but was not treated properly. This led to complications in the disease.

Red cell mass (secondary polycythemia) and hemostasis are components of cyanotic congenital heart disease, which, like TOF, is a multisystemic condition.[6,7,8] As a protective mechanism against arterial hypoxemia, secondary polycythemia increases the red blood cell count. To induce erythropoiesis, the kidneys secrete erythropoietin. At increased hematocrit levels, a state of balance is achieved. As a defense mechanism against hypoxia, erythrocytosis increases red blood cell production. Iron-deficient erythrocytosis increases the risk of thrombosis of the cerebral venous sinuses in cyanotic children under four years old.[6] Paradoxical emboli may induce strokes and transient ischemic episodes via the right-to-left shunts and are associated with congenital cardiac defects characterized by cyanosis.[8] She has the symptoms mentioned above, and this is proven by lab results. Her laboratory investigations revealed a hemoglobin of 17.1 g/dl and hematocrit of 50.3 % suggesting polycythemia.

Brain Abscess is a relatively unusual but potentially life-threatening infection of brain parenchyma, which can occur in around 5%–18.7% of the population with CHD. [10,11] The main predisposing factors are chronic hypoxia resulting in polycythemia, hyperviscosity, and poor host immunity. [13] It frequently presents with headache, fever, seizures, changes in mental status, focal neurological deficits, nausea, and vomiting. In developing countries, delay in surgical repair of TOF puts children at greater risk of developing adverse neurological complications, particularly brain abscess. Bypassing the pulmonary circulation, the blood in these patients is not filtered by normal alveolar phagocytes. This increases the probability of direct entrance of pathologic microorganisms into the circulation of the brain. This, together with the fact that the brain might be hypo-perfused due to severe hypoxemia and metabolic acidosis resulting from secondary polycythemia, allows the pathogens to seed such under-perfused regions.[11,13] Characteristically, hematogenous spread of this kind from a distant source is attributed to multiple cerebral abscesses. The patient came with headache, seizures, and right-sided paralysis. (CT) scan of the brain confirmed the diagnosis of brain abscess by demonstrating a well-defined ring-enhancing hypodense lesion in the right parieto-occipital region, measuring 1.5 x 1.5 x 1.5 cm

The delay in the diagnosis and consecutive

management of brain abscess in CCHD patients leaves the underlying condition unaddressed for a while sufficient to complicate the disease process. Mortality in untreated patients ranges from 27.5%–71%.[10] Larger or deep-seated abscesses should be aspirated immediately and repeatedly. Following aspiration, the patient should be started on appropriate antibiotic therapy specifically targeting the organism discovered in culture. Empirical medical therapy and operation are the exclusive treatment for these cases.[13] In this case, the patient was managed conservatively on intravenous antibiotics (ceftriaxone 2 × 2 g IV for 4-6 weeks and metronidazole 4 × 500 mg IV for 4-6 weeks, since the size of the abscess was small). She was also given acetaminophen (15 mg/kg/dose per oral six hourly), loading dexamethasone 10mg, followed 4x5mg iv tapp off per day.

Burr hole craniostomy and closed-system drainage (BCD) is a common surgical procedure in the field of neurosurgery. However, complications following BCD have seldom been reported. Burr hole craniostomy and closed-system drainage (BCD) have been widely used for the treatment. Because they are very simple procedures and can be performed even under local anesthesia with low complication rates.[14] Nevertheless, as many neurosurgeons experience and have been reported in many case reports,[14] devastating complications such as acute intracranial hematoma or surgical error occur at a frequency that cannot be ignored. Surgery or management errors occurred because drainage catheter malposition in the brain parenchyma occurred in this case. Burr hole craniostomy was performed in the parietal bone: the drainage catheter was inserted upwardly. Reoperation was performed in this case, but there were additional neurological deficits associated with catheter malposition. [14]

According to this case, intracranial hemorrhage occurred as an epidural hematoma and a subdural hematoma. Epidural hematoma is caused by tearing of the middle meningeal artery or venous injury of the dural sinuses or diploic veins.[14] These are the only possible complications related to stress of local forces. It is highly correlated with shear forces in surgical procedures or detachment between dura and the cranium.[14] It was revealed on immediate postoperative CT scans and was located near the burr hole site. In this patient, the symptom is seizure post-operation. A non-contrast head computed tomography (CT) scan on December 3, 2025, demonstrated a hyperdense, biconvex lesion in the left temporoparietal region with an estimated volume of 59.6 cc, causing a rightward midline shift of approximately 2.0 cm. Multiple hypodense lesions surrounded by hyperdense areas were observed in the left temporoparietal region.

The onset of acute SDH was detected on immediate postoperative CT scans, developed during hematoma drainage or immediately after the removal of the drainage catheter. We speculate that acute angle formation between the parenchymal surface and the drainage catheter that is made by parietal burr hole craniostomy, supine position, and advancement in an upward direction appears to contribute to parenchymal malposition of the drainage catheter.[14] Human errors such as opposite-side surgery should never occur; unfortunately, these errors have always existed because they are an inherent part of human behavior.[14] Systems to maximize patient safety are fundamental to reduce human errors.

A multidisciplinary treatment team (MDT) . MDTs create personalized treatment plans, improving patient outcomes, safety, and treatment adherence.

Internist Treatment for Secondary Polycytemia

The treatment approach in secondary polycythemia depends on the etiology involved. The general approach is the correction of the precipitating factors that will, in turn, lead to the correction of the hematologic abnormality.[15] Low-flow oxygen therapy can correct hypoxia and hence the secondary polycythemia. In patients with cyanotic heart disease, isovolumetric venesections have been recommended to be helpful in reducing viscosity. However, it should be kept in mind that excessive venesections are associated with iron deficiency.[16,17] In this patient, with hydration and vasodilators.

Cardiology Treatment for TOF

Neonates with severe RVOTO who present with profound hypoxemia and cyanosis will require prostaglandin therapy to maintain ductal patency and adequate pulmonary blood flow before a transcatheter intervention or surgical repair. Tet spells require a rapid and aggressive approach, including knee-chest positioning to increase systemic vascular resistance and "force" more blood into the pulmonary artery, oxygen therapy to cause pulmonary vasodilation, and decrease pulmonary vascular resistance. Patients may require intravenous fluid boluses to improve RV filling and increase pulmonary blood flow. They may also need intravenous beta-blockers to decrease heart rate to aid RV filling further and, sometimes, intravenous phenylephrine to increase systemic afterload. Morphine can also be given as a sedative during a tet spell, alleviating pain and anxiety and helping decrease heart and respiratory rates. A tet spell, left untreated, may lead to loss of consciousness and, ultimately, death. Surgical or transcatheter palliation and surgical repair aim to provide adequate and stable pulmonary blood flow.[18,19,20] In this patient, beta blockers, aspirin, and catheterization surgery are also planned for future therapy if the condition is more stable.

Neurology and Neurosurgeon Management for Cerebral Abscess, EDH and SDH

Non-operative treatment of brain abscesses has occasionally been proposed when the abscesses are multiple, inaccessible, or for high-risk surgical candidates. Furthermore, medical treatment consisting of antibiotics, steroids, and anticonvulsants is considered appropriate in abscesses measuring less than 2 cm in diameter, and the infecting organism is known. [24,25] However, some authors suggest that medical treatment alone could be reserved for abscesses <2.5 cm, if the patient is in good initial clinical condition (GCS >12) and when the etiology is well-known. Regarding our case, the borderline dimensions (2.4 cm), GCS <12, as well as the lack of surgical capabilities at that time, were the factors that led to a conservative approach.[24] CT and MRI brain imaging are essential for managing brain abscesses, as they aid in localizing the abscess and provide critical details, such as size and number. Depending on available surgical expertise, abscesses larger than 2 cm are typically considered for aspiration or excision. For multiple abscesses, management usually involves a prolonged course of high-dose antibiotics (4-8 weeks) with or without aspirations, guided by weekly CT scans. The antibiotic regimen should be carefully tailored based on the microorganisms isolated from the blood or abscess. Certain antibiotics, such as first-generation cephalosporins, aminoglycosides, and tetracyclines, are less effective for treating brain abscesses due to their limited ability to cross the blood-brain barrier.[24] Specific antibiotic regimens according to microorganisms are listed below: gram-positive bacteria, including streptococci: Third-generation cephalosporins (eg, cefotaxime and ceftriaxone) or penicillin G are effective; *S aureus* and *S epidermis*: These bacteria are usually associated with penetrating brain trauma or neurosurgical procedures and should be treated with vancomycin. Vancomycin is also effective for *Clostridium* species. Linezolid, trimethoprim-sulfamethoxazole, or daptomycin can be considered in cases of vancomycin resistance, Fungal infections: *Candida* and *Cryptococcus* must be treated with amphotericin B, Aspergillus and *Pseudallescheria boydii*: Voriconazole is the treatment of choice, *Toxoplasma gondii* infection: This is treated with pyrimethamine and sulfadiazine, which can be combined with highly active antiretroviral therapy (HAART) in cases of HIV. [24] Steroids may be considered in select cases to reduce mass effects, improve antibiotic penetration, and alleviate cerebral edema.[27] However, their use should be judicious, with careful consideration of potential benefits versus the risks of exacerbating an underlying infection, suppressing the immune response, or delaying wound healing.[24] In this patient with burr hole craniotomy surgery and antibiotics ceftriaxone and metronidazole.

The surgical approach plays a pivotal role in managing brain abscesses, with the choice of procedure depending on the operator's skill and preference. Techniques include ultrasound or

CT-guided needle aspiration via the stereotactic method, burr hole drainage, and craniotomy for loculated or multiple abscesses. Intravenous (IV) or intrathecal agents targeting specific microorganisms are often used with surgical therapy.[28] In this patient, the surgery caused epidural hemorrhage.[29]

Conservative treatment is given to an extradural hematoma when serial computed tomography facilities are readily available. Small extradural haematomas can be managed conservatively in minor head injury; these cases especially involve the frontal and parietal occipital region. However, follow up CT scan brain should be performed within 48 hours and at 2 weeks, many times when the patient determines. If there is deterioration, the patient should be operated upon. In the removal of an extradural haematoma, there was no mortality.[25] EDH is a neurosurgical emergency that often requires urgent surgical evacuation to prevent irreversible neurologic injury and death from hematoma expansion and herniation. Neurosurgical consultation should be obtained without delay, particularly in patients who meet the criteria for operative intervention. Outcomes worsen progressively with increasing time from the first recorded decline in consciousness to surgical decompression, with especially poor prognosis when this interval exceeds 2 hours.[27] Initial management should prioritize patient stabilization, addressing airway, breathing, and circulation as a matter of urgency.[25]In this patient, 48 hours after the first operation, a second operation was performed to drain the bleeding due to an epidural hematoma.

Conservative treatment of cSDH remains sparse and is predominantly of low evidence level. Steroids and tranexamic acid seem to be promising conservative modalities to treat cSDH. However, the efficacy of these medications is still based on a poor grade of evidence (mostly evidence grade III). ACE inhibitors were evaluated as only adjuvant therapy to surgery, and their effect on recurrence rate remains debatable. Even though ACE inhibitors lower VEGF levels in the haematoma cavity, their efficacy in treating cSDH remains unclear. Mannitol seems an effective conservative treatment modality; however, these data too are based on small retrospective case series and the long treatment duration is a major drawback. A platelet activating factor receptor antagonist was shown, with a low evidence grade, to promote the resolution of cSDH, especially in patients with hygromas or low-density haematomas on CT and without paresis at presentation. Lastly, atorvastatin seems to be a valid and safe option for the conservative treatment of asymptomatic or mildly symptomatic cSDH patients.[26] SDHs greater than 1 cm at the thickest point generally require rapid surgical treatment. Smaller SDHs may not require surgery. A large craniotomy, surgery through an opening created in the skull, is often required to remove the thick blood clot and to reach bleeding sites.[26]In this patient, after the second operation, the patient experienced motor aphasia and recurrent facial muscle spasms. A CT scan revealed a subdural hematoma. However, the family refused reoperation, so conservative treatment was administered with steroids, piracetam, and clobazam. The patient improved, and seizures disappeared within 3 days. The patient was discharged on the third day, but with residual neurological deficits in the form of right-sided paralysis and aphasia.

CONCLUSION

Accurate diagnosis of Tetralogy of Fallot (TOF) and early correction of the congenital cardiac defect are essential to reduce the risk of serious complications, including brain abscess, as occurred in this patient. In this case, the brain abscess was likely related to chronic hypoxia and blood hyperviscosity, which predispose to bacterial infection and impair immune function. Management of the brain abscess required prolonged antibiotic therapy and burr-hole surgery for pus drainage. However, this procedure is technically challenging and carries a significant risk of postoperative hemorrhage. The patient subsequently developed an epidural hematoma and required craniotomy. Following this intervention, rebleeding of the subdural hematoma occurred and was ultimately managed conservatively with piracetam and clobazam.

CONFLICT OF INTERESTS

All author declares no conflicts of interest related to this work.

REFERENCES

1. Winn HR. Brain abscess. In: Tunkel AR, Scheld WM, editors.Youmans and Winn neurological surgery. 7th ed. Philadelphia: Saunders Elsevier; 2017. p. e187-97.
2. Nathoo N, Nadvi SS, Naroton PK. Brain abscess; management and outcome analysis of a computed tomography era experience with 973 patients. World Neurosurg. 2011;75:716-26.
3. Octaviani D, Komari N, Estiasari R. Pola mikroba, sensitivitas antibiotik, dan keluaran jangka pendek abses serebri di RSUPN Cipto Mangunkusumo. J Neurona. 2012;29(4).
4. Mikaningtyas L, Sugianto P, Ardhi MS, Tripriyanggara A, Risqon N. Multiple brain abscesses with tetralogy of Fallot (TOF): a case report. Bali Med J. 2023;12(3):2555– 8.
5. Begum NNF, Sarker FR, Begum M, et al. Management of a critical case of double outlet right ventricle (DORV) and cerebral abscess by multiple interventions. JAFMC Bangladesh 2016;11:81–4, doi:http://dx.doi.org/10.3329/jafmc.v11i1.30679.
6. Perloff JK, Rosove MH, Child JS, Wright GB: Adults with cyanotic congenital heart disease: hematologic management. Ann Intern Med. 1988:109:406-13. 10.7326/0003-4819-109-5-406
7. Territo MC, Perloff JK, Rosove MH, Moake JL, Runge A: Acquired von Willebrand factor abnormalities in adults with congenital heart disease: dependence upon cardiopulmonary pathophysiological subtype. Clinical and Applied Thrombosis/Hemostasis. 1998, 4:257-61. 10.1177/107602969800400408
8. WO P: The Eisenmenger syndrome or pulmonary hypertension with reversed central shunt. Br Med J. 1958,2:755-62. 10.1136/bmj.2.5099.755
9. Stout KK, Broberg CS, Book WM, et al. Chronic heart failure in congenital heart disease: A scientific statement from the American Heart Association. Circulation. 2016, 133:770-801.
10. Pandian JD, Moosa NV, Cherian PJ, Radhakrishnan K. Brainstem abscess complicating tetralogy of Fallot successfully treated with antibiotics alone. Neurol India 2000;48:272–5.
11. Sethi S, Kapil S. Scalp block for brain abscess drainage in a patient with uncorrected tetralogy of Fallot. World J Clin Cases 2014;2:934–7, doi:http://dx. doi.org/10.12998/wjcc.v2.i12.934.
12. Atiq M, Ahmed US, Allana SS, Chishti KN. Brain abscess in children. Indian J Pediatr 2006;73:401–4, doi:http://dx.doi.org/10.1007/BF02758560.
13. Begum NNF, Sarker FR, Begum M, et al. Management of a critical case of double outlet right ventricle (DORV) and cerebral abscess by multiple interventions. JAFMC Bangladesh 2016;11:81 doi:http://dx.doi.org/10.3329/jafmc.v11i1.30679.
14. Hyun Seok Lee , Sang Woo Song , Young Il Chun , Woo Jin Choe , Joon Cho , Chang Taek Moon , Young-Cho Koh. Complications following burr hole craniostomy and closed-system drainage for subdural lesions. Korean J Neurotrauma . 2018 Oct 31;14(2):68–75. doi: 10.13004/kjnt.2018.14.2.68
15. Hocking WG, Golde DW. Polycythemia: evaluation and management. Blood Rev. 1989 Mar;3(1):59-65. [PubMed]
16. McMullin MF. Investigation and Management of Erythrocytosis. Curr Hematol Malig Rep. 2016 Oct;11(5):342-7. [PubMed]
17. Perloff JK, Marelli AJ, Miner PD. Risk of stroke in adults with cyanotic congenital heart disease. Circulation. 1993 Jun;87(6):1954-9. [PubMed]
18. Sun HY, Proudfoot JA, McCandless RT. Prenatal detection of critical cardiac outflow tract anomalies remains suboptimal despite revised obstetrical imaging guidelines. Congenit Heart Dis. 2018 Sep;13(5):748-56. [PMC free article] [PubMed]
19. Mawad W, Mertens LL. Recent advances and trends in pediatric cardiac imaging. Curr Treat Options Cardiovasc Med. 2018 Feb 21;20(1):9. [PubMed]
20. Refaat MM, Ballout J, Mansour M. Ablation of atrial fibrillation in patients with congenital heart disease. Arrhythm Electrophysiol Rev. 2017 Dec;6(4):191-194. [PMC free article] [PubMed]
21. Nathoo N, Narotam PK, Nadvi S, van Dellen JR. Taming an old enemy: a profile of intracranial suppuration. World Neurosurg. 2012;77:484–90. [DOI] [PubMed] [Google Scholar]
22. Carpenter J, Stapleton S, Holliman R. Retrospective analysis of 49 cases of brain abscess and review of the literature. Eur J Clin Microbiol Infect Dis. 2007;26:1–11. [DOI] [PubMed] [Google Scholar]
23. Yogev R, Bar-Meir M. Management of brain abscesses in children. Pediatr Infect Dis J. 2004;23(2):157–159. [DOI] [PubMed] [Google Scholar]
24. Arlotti M, Grossi P, Pea F, et al. Consensus document on controversial issues for the treatment of infections of the central nervous system: bacterial brain abscesses. Int J Infect Dis. 2010;14(Suppl 4):S79–S92. [DOI] [PubMed] [Google Scholar]
25. Naveed Ashraf, Khalid Mahmood. Conservative management of extradural hematoma in minor head injury. Pak. J. of Neurol. Surg. – Vol. 17, No. 2, Jul. – Dec., 2013
26. Jehuda Soleman, Fabio Nocera, Luigi Mariani. The conservative and pharmacological management of chronic subdural haematoma: a systematic review. Swiss Med Wkly. 2017;147:w14398. https://doi.org/10.57187/smw.2017.14398
27. Simjian T, Muskens IS, Lamba N, et al. Dexamethasone administration and mortality in patients with brain abscess: A systematic review and meta-analysis. World

Neurosurg. 2018 Jul;115:257-63. [PubMed]
28. Vieira E, Guimarães TC, Faquini IV, et al. Randomized controlled study comparing 2 surgical techniques for decompressive craniectomy: with watertight duraplasty and without watertight duraplasty. J Neurosurg. 2018 Oct;129(4):1017-23. [PubMed]
29. Mendelow AD, Karmi MZ, Paul KS, Fuller GA, Gillingham FJ. Extradural haematoma: effect of delayed treatment. Br Med J. 1979 May 12;1(6173):1240-2. [PMC free article] [PubMed]