Airway Stenting for Benign and Malignant Central Airway Obstruction: A Case Series

Sahat Halim[1,2*], Aziza Harris[1], Steffi Cong Andi Nata[1], Achmad Mudassir Muchlis[1,3], Almerveldy Azaria Dohong[1], Gurmeet Singh[1]

[1]Division of Respirology and Critical Care, Department of Internal Medicine, Faculty of Medicine, Universitas Indonesia - Cipto Mangunkusumo National Hospital, Jakarta, Indonesia.
[2]Division of Respirology and Critical Care, Department of Internal Medicine, Faculty of Medicine, Universitas Sumatera Utara, Medan, Indonesia.
[3]Faculty of Medicine, Universitas Muhammadiyah Palu, Indonesia.

Corresponding Author:
Sahat Halim, MD. Division of Respirology and Critical Care, Department of Internal Medicine, Faculty of Medicine, Universitas Sumatera Utara, Jl. Dr. Mansyur No. 5, Medan Baru, Medan 20155, Indonesia. Email: sahathalim88@gmail.com.

ABSTRACT

Central airway obstruction (CAO) is a life-threatening condition caused by malignant or benign processes involving the trachea and main bronchi. Bronchoscopic airway stenting is an established intervention to restore airway patency, relieve symptoms, and stabilize patients, particularly in urgent or critical settings. However, its clinical role varies according to underlying etiology and disease context.

We report a single-center case series of seven adult patients with symptomatic CAO who underwent bronchoscopic airway stenting. Six cases were associated with malignant disease, and one involved benign obstruction due to endobronchial tuberculosis. Interventions included rigid and/or flexible bronchoscopy, with adjunctive techniques such as balloon dilatation, cryotherapy, and argon plasma coagulation. Stent selection was individualized based on anatomical and etiological considerations. Airway stenting led to immediate improvement in respiratory status in all cases. In benign obstruction, stenting achieved sustained airway patency without significant complications. In malignant CAO, stenting served primarily as a palliative or bridging intervention, providing temporary stabilization and enabling further oncologic or supportive therapy. In critically ill patients, including those with impending airway collapse or post-cardiac arrest, stenting functioned as a lifesaving or salvage procedure. Complications included tumor ingrowth, mucus retention, and infection; no fatal stent-related procedural events occurred.

Airway stenting is a versatile and effective modality for managing CAO. Its role differs by etiology, offering durable benefit in benign disease, palliative or stabilizing effects in malignancy, and potential life-saving intervention in selected critically ill patients. Individualized decision-making and multidisciplinary management remain essential to optimize outcomes.

Keywords: *Central airway obstruction; airway stenting; interventional pulmonology; malignant airway obstruction; benign airway stenosis; case series*

INTRODUCTION

Central airway obstruction (CAO) is a potentially life-threatening condition resulting from intrinsic tumor growth, extrinsic compression, or mixed airway compromise involving the trachea and main bronchi.[1,2] Clinically, patients may present with progressive dyspnea, cough, wheezing, hemoptysis, recurrent

post-obstructive pneumonia, or, in advanced cases, acute respiratory failure.[1]

The etiologies of CAO are broadly categorized as malignant or benign. Malignant CAO most commonly results from primary lung cancer, metastatic disease, or mediastinal invasion,[3] whereas benign causes include post-inflammatory fibrosis, post-tuberculosis stenosis, and iatrogenic airway injury.[4,5] This distinction is clinically important because the goals, expected durability, and timing of intervention often differ by underlying etiology.

Interventional bronchoscopy has become a cornerstone in the management of CAO.[1,2] Available modalities include mechanical debulking, cryotherapy, argon plasma coagulation (APC), balloon dilatation, and airway stenting, which may be used individually or in combination to restore airway patency.[2,6] Among these approaches, airway stenting is particularly valuable in cases of persistent structural narrowing, significant extrinsic compression, or high risk of restenosis after endoluminal recanalization.[2,6] By providing immediate mechanical support, stents can rapidly improve ventilation, relieve dyspnea, and stabilize patients at risk of respiratory deterioration.[2]

The clinical objectives of airway stenting vary according to etiology and prognosis. In malignant CAO, stenting is commonly performed with palliative intent to alleviate symptoms and facilitate further oncologic therapy.[2,3] In benign CAO, the goal is often durable airway stabilization and long-term patency.[4,5] In selected cases of impending airway collapse or critical extrinsic compression, stenting may also serve as a life-saving or rescue intervention.[7] Despite advances in technique and stent technology, outcomes remain heterogeneous and are influenced by tumor biology, comorbidities, airway anatomy, and procedural timing.[2]

Real-world case series that illustrate diverse indications, ranging from benign stenosis to advanced malignancy and salvage scenarios, offer valuable insight into contemporary airway decision-making. In this case series, we highlight the spectrum of indications for airway stenting, including palliative, lifesaving, and salvage applications, and examine factors influencing procedural success and durability in modern airway management.

CASE ILLUSTRATION

This retrospective single-center case series included all consecutive adult patients with symptomatic central airway obstruction (CAO) who underwent bronchoscopic airway stent placement by the Interventional Pulmonology Team in the Operating Theater of Dr. Cipto Mangunkusumo National Referral Hospital (RSCM), Jakarta, Indonesia, between January and December 2025. Consecutive sampling was applied, whereby all eligible patients requiring airway stenting during the study period were included. CAO was confirmed by bronchoscopy and/or imaging, and stenting was performed in patients requiring airway stabilization or in those considered unsuitable for surgical management. Six patients had malignant CAO, and one had benign obstruction secondary to endobronchial tuberculosis. Written informed consent for the procedure and publication of anonymized clinical information was obtained from all patients. Most patients presented with progressive dyspnea, and one required salvage stenting following peri-procedural cardiac arrest. Key clinical characteristics and outcomes are summarized in **Table 1**.

Case 1

An 80-year-old woman with stage IV lung adenocarcinoma presented with progressive dyspnea. She had a history of CAO requiring prior airway stent placement and had received multiple oncologic treatments, including immunotherapy and chemotherapy. Evaluation showed recurrent CAO involving the right main bronchus and its branches, with near-complete luminal compromise caused by tumor ingrowth within the previously placed stent. This was accompanied by right-sided pleural effusion and lobar atelectasis.

The patient underwent therapeutic bronchoscopy with repeat locoregional intervention, including radiofrequency ablation, to relieve airway obstruction. The procedure resulted in temporary clinical improvement,

Table 1. Clinical characteristics, mechanisms of obstruction, stent types, and outcomes.

Case	Age (years)/ Sex	Primary Etiology	Mechanism of Obstruction	Location of Obstruction	Stent Type	Stent Location	Immediate Outcome	Complications
1	80/F	Stage IV lung adenocarcinoma	Tumor ingrowth within prior stent ± extrinsic compression	Right main bronchus	Metallic	Right main bronchus to upper or intermediate bronchi	Symptomatic improvement	Tumor ingrowth, mucus retention, pleural effusion
2	57/M	Endobronchial tuberculosis	Inflammatory stenosis	Trachea and both main bronchi	Silicone Y-stent	Tracheobronchial (Y configuration)	Sustained symptom resolution	None observed
3	68/M	Anaplastic thyroid carcinoma	Severe extrinsic compression	Upper thoracic trachea	Metallic	Trachea	Airway stabilization	Post-op pneumonia (non-stent related)
4	67/M	Recurrent laryngeal SCC	Intrinsic malignant obstruction ± extrinsic compression	Right main bronchus	Metallic	Right main bronchus	Restored airway patency	Pneumonia, tumor-related bleeding
5	49/F	Metastatic cervical SCC	Extrinsic compression + intraluminal tumor	Right main bronchus	Metallic	Right main bronchus	Immediate respiratory improvement	Infection, mucus retention, disease progression
6	75/M	Pulmonary tuberculosis with suspected lung malignancy	Intrinsic obstruction with bleeding	Left main bronchus	Metallic	Left main bronchus to lower lobe bronchus	Dyspnea and hemoptysis resolved	None observed
7	66/M	Advanced lung cancer	Intrinsic malignant obstruction	Right main bronchus	Metallic	Right main bronchus to bronchus intermedius	Salvage airway restoration	Septic shock, multiorgan involvement

with partial relief of dyspnea and stabilization of oxygenation. During follow-up, however, disease progression continued, with recurrent obstruction, pleural effusion, and ongoing respiratory compromise. The intervention, therefore, served primarily as a palliative measure, providing transient airway patency and symptomatic relief without preventing further deterioration.

Case 2

A 57-year-old man with pulmonary tuberculosis on anti-tuberculosis treatment, then in month 6 of therapy, and prior Y-stent placement for endobronchial involvement, presented with acute chest pain. Evaluation confirmed the presence of a previously placed Y-shaped airway stent extending from the trachea to both main bronchi, with underlying endobronchial disease. Radiographic findings demonstrated persistent pulmonary abnormalities, including cavitary consolidation and nodular opacities, consistent with active infectious and structural lung disease (**Figure 1A–B**). No significant intraluminal obstruction of the stent was identified, suggesting preserved airway patency.

The patient had previously undergone therapeutic bronchoscopy with airway stenting to manage central airway compromise related to endobronchial tuberculosis (**Figure 1C–E**). This intervention stabilized airway patency and prevented further respiratory deterioration. During follow-up, the stent remained patent without evidence of acute airway-related complications. The intervention therefore provided durable airway stabilization, allowing continued medical management of the underlying disease.

Case 3

A 68-year-old man with a progressively enlarging thyroid mass presented with worsening dyspnea. He also reported hoarseness, dysphagia, and significant weight loss. Evaluation revealed CAO involving the upper trachea, with approximately 70–80% stenosis due to

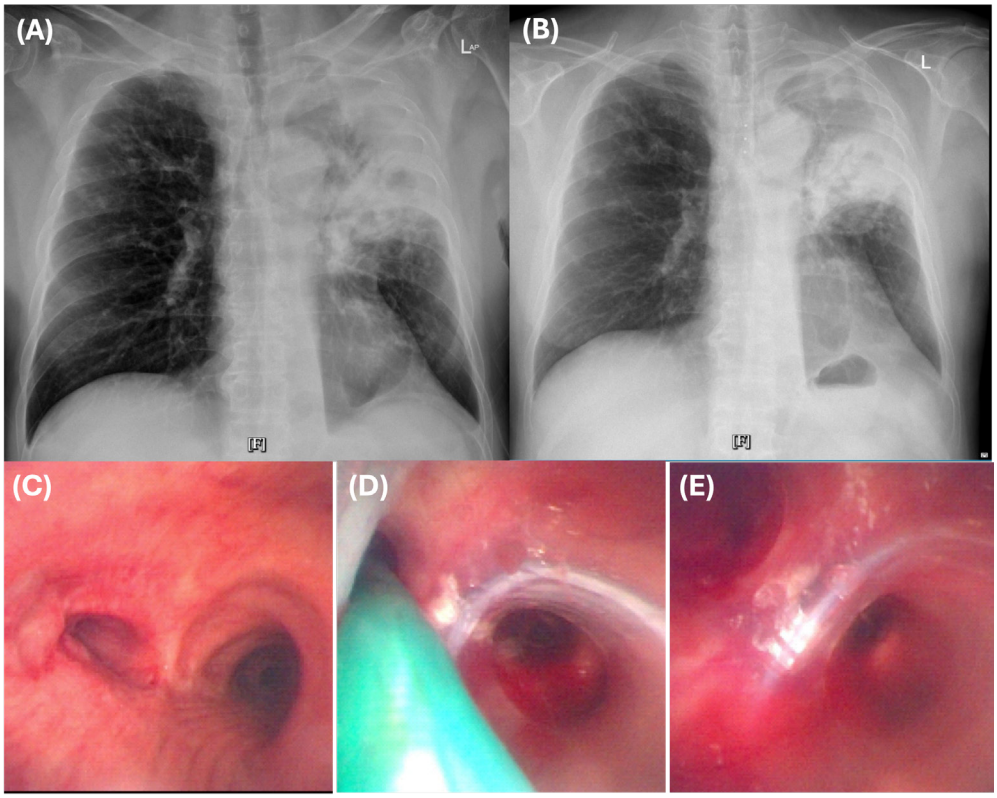

Figure 1. Radiologic and bronchoscopic findings before and after airway stenting in Case 2. (A) Pre-procedural chest radiograph showing heterogeneous opacity in the left lung field, suggestive of airway obstruction with associated parenchymal changes. (B) Post-stenting chest radiograph demonstrating interval stabilization of lung aeration, with visualization of the airway stent along the tracheobronchial axis. (C) Pre-intervention bronchoscopy showing significant luminal narrowing consistent with tracheobronchial stenosis. (D) Intra-procedural view during stent deployment, with the delivery system in place and partial restoration of the airway lumen. (E) Post-stenting bronchoscopy demonstrating improved airway patency, with the stent in situ and adequate luminal expansion.

external compression and infiltration from a large malignant thyroid mass with intrathoracic extension. Additional findings included tracheal deviation, vocal cord paresis, and cervical lymphadenopathy, consistent with advanced thyroid malignancy.

The patient underwent therapeutic bronchoscopy with balloon dilatation, followed by placement of a tracheal airway stent to relieve critical airway narrowing (**Figure 2**). The procedure resulted in immediate stabilization of the airway and allowed optimization of ventilatory support. During follow-up, the clinical course was complicated by ventilator-associated pneumonia and infectious complications; however, the airway stent remained in place and maintained patency. The intervention functioned as both a life-saving and palliative measure, preventing CAO and enabling continued supportive and oncologic management.

Case 4

A 67-year-old man with laryngeal squamous cell carcinoma status post total laryngectomy and incomplete chemoradiotherapy presented with massive hemoptysis and progressive dyspnea. Evaluation revealed CAO involving the right main bronchus, with complete occlusion of the right upper lobe bronchus due to recurrent malignant disease with mediastinal extension, resulting in obstructive atelectasis.

The patient underwent therapeutic bronchoscopy with tumor recanalization and balloon dilatation, followed by placement of a bronchial stent in the right main bronchus. This restored airway patency and improved respiratory status. During follow-up, the clinical course was complicated by pneumonia and tumor-related bleeding; however, the patient showed clinical improvement, with resolution of dyspnea and stabilization of hemoptysis. The intervention

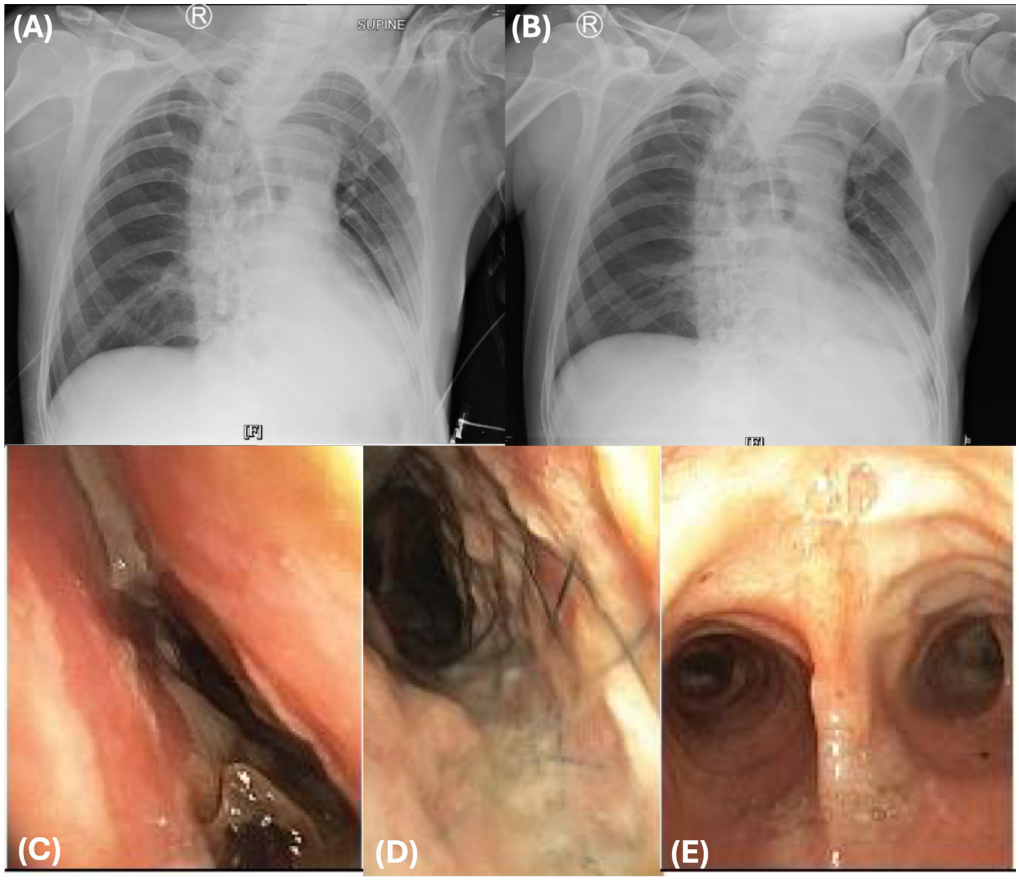

Figure 2. Imaging and bronchoscopic findings in tracheal stenosis treated with balloon dilatation and airway stenting in Case 3. (A) Pre-procedural chest radiograph demonstrating left-sided opacity with features consistent with airway obstruction and associated lung collapse. (B) Post-procedural chest radiograph showing partial re-expansion and improved aeration following airway intervention. (C) Bronchoscopic view before intervention demonstrating severe tracheal narrowing, with a slit-like lumen due to external compression. (D) Intra-procedural bronchoscopic image showing bronchial stent placement within the stenotic airway segment. (E) Post-intervention bronchoscopic view demonstrating improved airway patency, with a widened and more symmetric lumen.

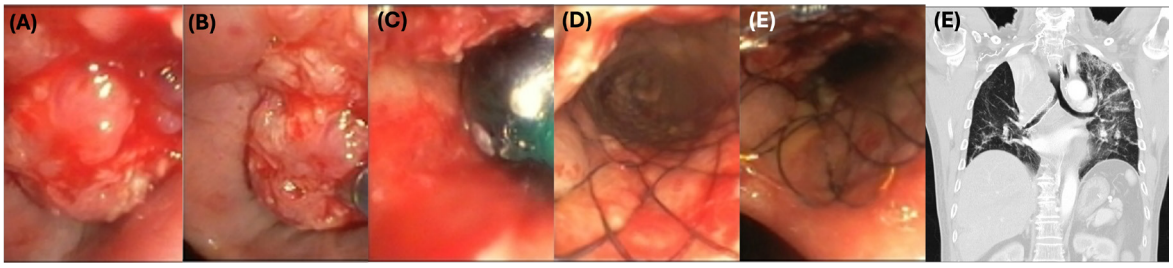

Figure 3. Radiographic and bronchoscopic findings of malignant central airway obstruction in Case 4. (A) Endobronchial mass causing significant luminal obstruction. (B) Cryodevitalization of the lesion. (C) Balloon dilation to restore airway patency. (D-E) Bronchial stent placement with optimal positioning. (F) Post-procedural chest CT scan demonstrating improved airway patency after stent insertion. The obstruction was caused by intrinsic malignant involvement with possible extrinsic compression.

functioned as a palliative measure, maintaining airway patency and allowing continuation of supportive and oncologic care.

Case 5

A 49-year-old woman with advanced cervical cancer, suspected stage IVA, and known intrabronchial metastasis presented with acute progressive dyspnea. Evaluation revealed CAO involving the right main bronchus with approximately 65% stenosis, accompanied by multiple pulmonary nodules, mediastinal lymphadenopathy, and associated atelectasis.

The patient underwent therapeutic bronchoscopy with tumor debulking using cryotherapy and APC, followed by placement of an airway stent in the right bronchial system. This led to improvement in dyspnea and oxygenation. During follow-up, the clinical course was complicated by recurrent infection, mucus retention, and progressive metastatic disease, causing persistent airway compromise. The intervention provided temporary symptomatic relief and functioned primarily as a palliative measure.

Case 6

A 75-year-old man with clinically diagnosed pulmonary tuberculosis with incomplete treatment and a significant smoking history presented with progressive dyspnea and intermittent hemoptysis. Evaluation revealed CAO involving the left main bronchus, with approximately 80% stenosis and complete occlusion of the left upper lobe bronchus, associated with a suspected malignant lung mass and lobar atelectasis.

The patient underwent therapeutic bronchoscopy with tumor debulking using cryotherapy and APC, followed by placement of a metallic airway stent in the left main bronchus extending to the lower lobe bronchus. The procedure restored airway patency and improved respiratory status. During follow-up, the patient showed clinical improvement, with resolution of dyspnea and stabilization of hemoptysis. The stent remained patent, and the intervention functioned as an effective palliative measure while further oncologic evaluation was pending.

Case 7

A 66-year-old man with lung cancer and prior bronchoscopic intervention presented with severe respiratory failure and hemodynamic instability requiring mechanical ventilation and vasopressor support. Evaluation revealed CAO involving the right main bronchus, with significant intraluminal stenosis associated with a malignant mass and compressive atelectasis.

The patient underwent therapeutic bronchoscopy with tumor debulking, followed by placement of a metallic airway stent in the right main bronchus extending to the bronchus intermedius under fluoroscopic guidance. This restored airway patency and stabilized ventilation. During follow-up, the clinical course was complicated by septic shock and multiorgan involvement. The intervention functioned as both a life-saving and palliative measure, maintaining airway patency in a critically ill patient.

DISCUSSION

Malignant CAO remains a clinically challenging and progressive condition. For patients who are not surgical candidates, the therapeutic goal is primarily palliative.[2,3] Bronchoscopic interventions, including airway stenting, are therefore directed toward rapid restoration of airway patency, relief of dyspnea, and improvement in oxygenation.[2,4,8,9] Consistent with prior reports, outcomes in malignant CAO are largely determined by tumor biology and response to therapy.[2] In our case series, patients with malignant CAO (Cases 1 and 3–7) experienced symptomatic improvement after stenting, although the durability of the benefit was often limited by continued disease progression.

By contrast, benign CAO, as illustrated by Case 2, is typically driven by inflammatory and fibrotic mechanisms. In this setting, the objective is durable airway restoration rather than palliation.[4,5] The sustained clinical improvement observed after silicone Y-stent placement supports previous evidence that stenting in benign disease may provide longer-term benefit.[2,10] These contrasting outcomes emphasize that airway stenting serves different therapeutic intents depending on the underlying etiology.

Case 3 illustrates the role of airway stenting in impending airway collapse caused by severe extrinsic compression from anaplastic thyroid carcinoma.[2,7] Given the aggressive nature of this malignancy,[7] stenting functioned as an emergency rescue measure, preventing acute respiratory failure and enabling postoperative stabilization and further oncologic management. In such scenarios, airway stenting may be lifesaving rather than purely palliative.

Salvage airway stenting in critically ill patients is further exemplified by Case

7, in which cardiac arrest occurred during the clinical course before definitive airway stabilization.[11] After hemodynamic stabilization, delayed stent deployment under fluoroscopic guidance was technically feasible and restored airway patency.[7,12] This case underscores the importance of multidisciplinary coordination and demonstrates that re-intervention can be clinically meaningful even in unstable patients.[7]

Stent selection should be individualized according to etiology, airway anatomy, and therapeutic goals.[6] Silicone stents are generally preferred in benign CAO because they are removable and associated with a lower risk of granulation tissue formation, as shown in Case 2.[4,6] Conversely, self-expanding metallic stents are often favored in malignant CAO, as in Cases 1 and 3–7, because of their conformability and resistance to extrinsic compression.[2,6,10] Our experience aligns with published recommendations supporting tailored stent selection rather than a uniform approach.[6,7]

Complications in this series were consistent with prior reports and included tumor ingrowth, mucus retention, and infection.[2,4,11] Tumor ingrowth was observed in Case 1, while tumor-related bleeding in Case 4 and recurrent infection with mucus retention in the setting of advanced metastatic disease in Case 5 further highlight the complex post-stenting course in malignant CAO. Although severe adverse events such as migration, pneumothorax, and perforation are uncommon, stent migration may be life-threatening when it occurs.[2,11] These findings emphasize the need for careful sizing, close surveillance, and routine airway toilet to maintain long-term patency.[2,6,13] Importantly, airway stenting does not alter the natural course of malignancy and should be regarded as supportive or bridging therapy.[2]

Beyond symptom relief, airway stenting may facilitate further oncologic or supportive treatment by stabilizing respiratory status.[1,2] Restoration of airway patency can permit chemotherapy or radiotherapy that might otherwise be contraindicated because of respiratory compromise.[2,5] Optimal outcomes depend on timely intervention, appropriate patient selection, and experienced multidisciplinary airway management.[5]

This series encompasses a broad spectrum of CAO, including benign inflammatory stenosis, intrinsic malignant obstruction, extrinsic compression, and salvage intervention in critically ill patients. This heterogeneity reflects the diverse real-world applications of airway stenting and highlights the importance of tailoring the procedure to the clinical context.

Several limitations warrant consideration. As a retrospective single-center case series, this study is subject to selection bias and lacks standardized outcome measures. The small sample size limits generalizability, and outcomes in malignant cases were influenced by tumor biology and concurrent therapies. Despite these limitations, the series provides practical insight into procedural feasibility and individualized airway decision-making.

Overall, airway stenting should not be regarded as a uniform procedure, but rather as an etiology-dependent strategy requiring individualized decision-making. In benign disease, the goal is durable airway patency; in malignant obstruction, palliation and facilitation of oncologic therapy; and in critical illness, rescue stabilization. This spectrum-based approach underscores the importance of individualized management within a multidisciplinary airway team.

CONCLUSION

Airway stenting is a versatile component of interventional bronchoscopy in the management of CAO. In malignant disease, it primarily serves as a palliative or bridging intervention, whereas in benign obstruction, it may provide durable airway stabilization. In selected critically ill patients, it can function as a life-saving or salvage procedure. This case series demonstrates that airway stenting should be approached as an individualized therapeutic strategy rather than a standardized intervention, with decision-making guided by disease etiology, airway anatomy, clinical goals, and multidisciplinary assessment.

ACKNOWLEDGMENTS

The authors would like to express their sincere gratitude to all pulmonology fellows, especially Rio Gusta Notario Besri, MD; Kreisty Sisilya Zyully Saerang, MD; Anwar Sholeh, MD; Jorgen Gottlieb Alessandro Pamantung, MD; and Mohammad Sadhyo Prabhasworo, MD, for their invaluable guidance, support, and insightful contributions throughout this work. The authors also extend their sincere appreciation to all internal medicine residents for their collaboration, encouragement, and assistance during the completion of this study.

CONFLICT OF INTERESTS

The authors declare no conflict of interest.

REFERENCES

1. Ernst A, Feller-Kopman D, Becker HD, Mehta AC. Central airway obstruction. Am J Respir Crit Care Med. 2004 Jun 15;169(12):1278–97. doi:10.1164/rccm.200210-1181SO
2. Leonardi B, Fasano M, Vicario G, et al. Is airway stent a definitive treatment for management of malignant central airway obstruction? Ann Thorac Surg Short Rep. 2026 Jan; S2772993126000070. doi:10.1016/j.atssr.2025.12.013
3. Ortiz-Comino RM, Morales A, López-Lisbona R, Cubero N, et al. Silicone stent versus fully covered metallic stent in malignant central airway stenosis. Ann Thorac Surg. 2021 Jan;111(1):283–9. doi:10.1016/j.athoracsur.2020.04.141
4. Leksana JS, Khairsyaf Oea, Afriani. Airway stent in lung cancer: A narrative literature review. Biosci Med J Biomed Transl Res. 2022 Nov 3;6(14):2682–90. doi:10.37275/bsm.v6i14.665
5. Mahmood K, Frazer-Green L, Gonzalez AV, et al. Management of central airway obstruction. CHEST. 2025 Jan;167(1):283–95. doi:10.1016/j.chest.2024.06.3804
6. Folch E, Keyes C. Airway stents. Ann Cardiothorac Surg. 2018 Mar;7(2):273–83. doi:10.21037/acs.2018.03.08
7. Su S, Liang L, Liu Z, Wang L, Zhang T, Chen N. Extracorporeal membrane oxygenation as life-saving bridge for patients with airway obstruction caused by neck and chest tumors to salvage procedure: an in-depth review. Int J Surg. 2025 Jan;111(1):1090–100. doi:10.1097/JS9.0000000000002008
8. Benn BS. Therapeutic bronchoscopy facilitates liberation from mechanical ventilation and improves quality of life for critically ill patients with central airway obstruction. J Thorac Dis. 2021 Aug;13(8):5135–8. doi:10.21037/jtd-2019-ipicu-16
9. Saad CP, Murthy S, Krizmanich G, Mehta AC. Self-expandable metallic airway stents and flexible bronchoscopy. Chest. 2003 Nov;124(5):1993–9. doi:10.1378/chest.124.5.1993
10. Lachkar S, Couraud S, Salaün M, et al. Self-expanding metallic Y-stent compared to silicone Y-stent for malignant lesions of the main carina: A single center retrospective study. Respir Med Res. 2020 Nov;78:100767. doi:10.1016/j.resmer.2020.100767
11. Agrawal A, Agarwal A, Kagebein S, Persaud L, Meena N. To stent or not to stent and if stented when to remove it? Glimpse of interventional pulmonology conundrums with an illustrative series. J Cancer Sci Res. 2016. doi:10.4172/2576-1447.1000S1-005
12. Sethi S, Gildea TR, Almeida FA, Cicenia JC, Machuzak MS. Clinical success stenting distal bronchi for "Lobar Salvage" in bronchial stenosis. J Bronchol Interv Pulmonol. 2018 Jan;25(1):9–16. doi:10.1097/LBR.0000000000000422
13. Bashour SI, Lazarus DR. Airway stents in interventional pulmonology. J Respir. 2024 Mar 1;4(1):62–78. doi:10.3390/jor4010006