

Diabetic Gastroenteropathy: A Complication of Diabetes Mellitus

Alvin H. Kurniawan, Benedictus H. Suwandi, Ulfa Kholili

Department of Internal Medicine, Faculty of Medicine Airlangga University – Dr. Soetomo General Hospital, Surabaya, Indonesia.

Corresponding Author:

Ulfa Kholili, MD. Division of Gastroenterohepatology, Department of Internal Medicine, Faculty of Medicine, Airlangga University - Dr. Soetomo General Hospital. Jl. Mayjen Prof. Dr. Moestopo no. 6-8, Surabaya 60286, Indonesia. email: ulfakholili1975@gmail.com.

ABSTRAK

Gastroenteropati diabetik merupakan hal yang sering terjadi pada pasien diabetes melitus lama, terutama pada pasien yang dengan kontrol glikemi yang buruk maupun yang telah memiliki komplikasi lain, termasuk semua bentuk komplikasi diabetes pada saluran gastrointestinal, dimana menyebabkan berbagai keluhan seperti heartburn, nyeri perut, mual, muntah, bahkan sampai konstipasi, diare, dan inkontinensia fekal. Hal yang mendasari komplikasi ini berbeda-beda pada setiap organ maupun keluhan, seperti neuropati sistem saraf otonom yang, hilangnya Sel Interstitial Cajal sebagai pacemaker jaringan otot gaster sehingga menimbulkan dismotilitas, gangguan transportasi cairan dan fungsi motorik, serta hiperglikemia yang menyebabkan stres oksidatif, dan juga faktor lain seperti insulin-growth factor I yang mengakibatkan atrofi otot polos. Gastroenteropati diabetik secara jelas merupakan salah satu penyebab morbiditas pada pasien diabetes melitus. Diagnosis dari komplikasi gastroenteropati diabetik sangat perlu dicermati dan penting untuk menyingkirkan kemungkinan-kemungkinan lainnya. Manajemen dari komplikasi juga perlu diperhatikan dengan teliti karena selain menyelesaikan keluhan juga perlu menjaga kontrol glikemi yang baik. Dengan semakin meningkatnya jumlah pasien diabetes melitus dan prevalensi komplikasi gastroenteropati pada pasien diabetik masih belum tercatat jelas, disebabkan perhatian dan pengetahuan yang kurang oleh tenaga medis dalam mengenali bentuk komplikasi gastroenteropati; penting untuk dapat mengenali dan menangani secara dini pada pasien gastroenteropati diabetik agar dapat meningkatkan kualitas hidup dan penanganan diabetes yang baik.

Kata kunci: diabetes melitus, gastroenteropati, komplikasi, gastroparesis

ABSTRACT

Diabetic gastroenteropathy is a common complication in prolonged diabetic patients, particularly patients with poor glycemic control or other complications, including all form of diabetic complication on the gastrointestinal tract, which prompts various symptoms of heartburn, abdominal pain, nausea, vomiting, even constipation, diarrhea, and fecal incontinence. The underlying pathophysiology of this complication manifestations are different on each organ or symptom, but may include autonomic nervous system neuropathy, loss of Interstitial Cell of Cajal as gastric muscle pacemaker leading to dysmotility, impair of liquid transportation and motoric function, as well as hyperglycemia causing oxidative stress, and other factors like Insulin-Growth Factor I inducing smooth muscle atrophy. Diabetic gastroenteropathy is one of major morbidity on diabetes mellitus patients. Patients with this complication need to be well diagnosed and ruled out other diagnosis possibilities. Management of the complication includes resolving main symptoms and maintaining good glycemic control. With growing number of diabetes mellitus patients and the prevalence of diabetic gastroenteropathy complication

not being well recorded, caused by lack of attention and knowledge of healthcare provider in identifying the complication; it is important to be able to identify and to give early treatment to diabetic gastroenteropathy patients, to increase quality of life and maintain glycemic control of the patient.

Keywords: *diabetes mellitus, gastroenteropathy, complication, gastroparesis.*

INTRODUCTION

Diabetic gastroenteropathy is one of the most common complications in prolonged diabetic patients, particularly in patients either with poor glycemic control or with other complications concurrently. Diabetic gastroenteropathy as a complication of diabetes mellitus includes all form of diabetic complication on the gastrointestinal tract, which causes various symptoms involving heartburn, abdominal pain, nausea, vomiting, even constipation, diarrhea, and fecal incontinence. These symptoms significantly impair patients' quality of life, as well as increasing patients' morbidity from dehydration, electrolyte imbalance, and poor glycemic control.¹⁻³

While diabetes mellitus global prevalence is increasing from 424.9 million patients in 2017 to the estimated 628.9 million by 2045 because of urbanization, lifestyle, and the tendency of obesity,⁴ the prevalence of diabetic gastroenteropathy is still not well recorded.¹ This could be due to lack of attention and knowledge of healthcare provider in identifying gastroenteropathy as a diabetic complication. Therefore, it is important to be able to identify and to early treat diabetic gastroenteropathy patients, to increase the quality of life and diabetic control of the patient.

In this literature, there will be explanations about complication manifestation, approach, and management in treating gastrointestinal complications in diabetic patients which divided by organ.

EPIDEMIOLOGY

The data of gastroenteropathy complication in diabetic patients is not readily available for the time being, but there was some research in the third level referral center which showed deviation from data collected in the lower level of health center. This is shown by the discordance

of diabetic gastroenteropathy prevalence in the diabetes clinic of third level referral center as high as 76%-83%,⁵ whereas in community level or lower, mentioned symptoms only recorded as 5-12%.³ On each symptom, esophagus prevalence was recorded as high as 63% on dysmotility and 41% on reflux.^{6,7} Gastroparesis is one of the most complained symptoms, but the data in each research varied from 5 to 18 percents.^{8,9} On the intestinal symptoms, the majority of 60% was diagnosed with constipation followed by 20% of diarrhea complaint from diabetic patients. Differences in prevalence recorded probably due to lack of attention to recognize the signs and symptoms of gastroenteropathy, which brings us to the importance of knowing and treating the diabetic gastroenteropathy better.¹⁰

PATHOPHYSIOLOGY

The underlying pathophysiology on every diabetic gastroenteropathy manifestations is different on each organ or symptom. However, from every existing factor, autonomic neuropathy is the one most important aspect of the symptoms. Neuropathy on gastrointestinal tract can affect all organs as shown on **Figure 1**. Gastrointestinal neuropathy can affect vagal nerve, sympathetic and parasympathetic nervous system, or innervations of anal sphincter.^{5,11} Neuropathy on the autonomic nervous system is commonly found simultaneously progressing in chronic diabetes due to prolonged hyperglycemia.¹²

One of the neuropathies that have been discovered is the neuropathy of parasympathetic autonomic nervous system, vagal nerve with Wallerian degeneration, decrease of density and diameter of unmyelinated axons, thickening of Schwann's Cell basal lamina, and decrease of collagen fibrils thickness, also abnormal endoneurial capillaries are found on diabetic patients.^{13,14} Autonomic neuropathy also affects the Interstitial Cell of Cajal (ICC) that has

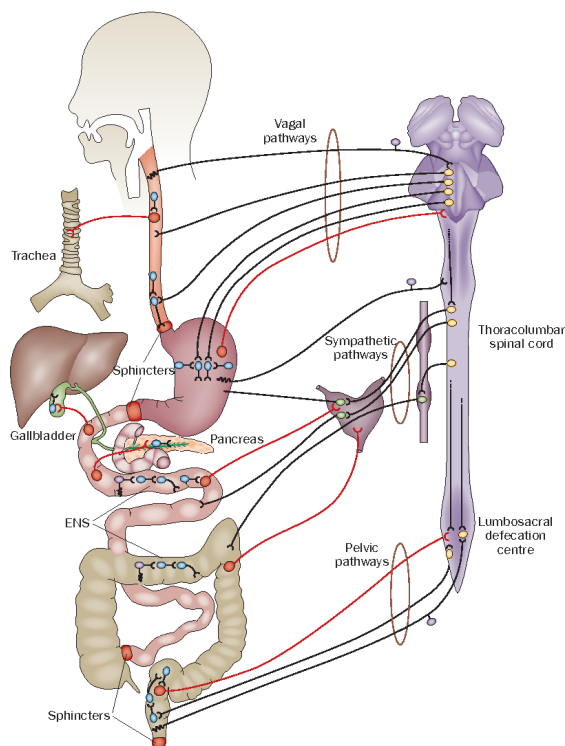


Figure 1. Innervation of gastrointestinal tract.¹³

been confirmed by researches on animal and human.¹⁵ ICC is the pacemaker of gastric muscle tissue, from which slow wave will start and then distributed in all directions with equal velocity.¹⁶ On diabetic patients, significant loss of ICC has been proved by gastric wall biopsies will promote an electrical dysrhythmia which later induces dysmotility symptoms such as dysphagia, gastroparesis, or constipation.¹⁷

Neuropathy also occurs on the sympathetic autonomic nervous system causing the impairment of liquid transportation and motoric function that lead to rapid bowel transit. This impairment of sympathetic nervous system not only manifests on bowel transit but also on α 2-adrenergic, which controls internal anal sphincter tone, that will promote symptoms like fecal incontinence or nocturnal incontinence. Both sympathetic and parasympathetic nerve neuropathy may partially explain paradoxical symptoms such as diarrhea and constipation.^{18,19}

Hyperglycemia is another underlying factor of the impaired gastrointestinal tract on diabetic patients. Hyperglycemia will cause oxidative stress from the imbalance of pro-oxidative

and anti-oxidative factors. This imbalance will inhibit the neurite growth on the nerve that causes neurite degeneration (decrease of caliber, beading, and growth cone retraction) and also neuron apoptosis.¹³ Additionally, there are also factors like insulin-growth factor I, inducing an atrophic change of smooth muscle structure leading to decreased gastrointestinal functions.²⁰

SYMPTOMS MANIFESTATION

Manifestation on Esophagus

Symptoms of esophagus impairments in diabetic patients are dysphagia, heartburn, even odynophagia. Dysphagia and heartburn are the manifestations from esophagus motoric function disorder in peristaltic movement or lower esophagus sphincter tone. This will lead to dilation of esophagus, gastric reflux, and even stalling of esophagus emptying.²¹ While odynophagia is commonly caused by candida esophagitis.¹³ Diabetic patients are often under an immunocompromised condition, so that opportunistic infection may emerge, including candida infection on esophagus.²²

Disorder of esophagus motoric function is prompted by neuropathy complication of myenteric plexus, which regulates the activity of smooth muscle fibers in esophagus and lower esophageal sphincter. Then, this neuropathy affect remodeling of muscle structure in diabetic patients, which leads to esophageal motility disorder such as abnormal peristaltic movement, spontaneous contraction, and decreased lower esophageal sphincter tone.²³

Heartburn is associated with gastroesophageal reflux in the diabetic patient, as high as 41%. Patients with neuropathy are more likely to be found with erosive esophagitis than the ones without neuropathy. Despite the high prevalence of erosive esophagitis and dysmotility, only a few give rise to symptoms, while a lot of others go asymptomatic. Therefore, gastroscopy is needed to confirm a diagnosis.²⁴

Latterly complaint of odynophagia in diabetic patients should be thought as candida esophagitis. This diagnosis can be more confirmed if there are other findings like a plaque or typical stomatitis of oral candidiasis. However, to be noted that

candida esophagitis can be found without oral candidiasis.¹³ Another possibility of odynophagia cause is other esophagitis such as viral, bacterial, or parasitic, in few cases. Further examination such as endoscopy is needed to ensure the causative diagnosis.²⁵

Management

Further examinations are needed for esophageal manifestation including endoscopy to diagnose erosive esophagitis or candida esophagitis and the examination of reflux and dysmotility such as pH-meter and manometry.^{10,13} With endoscopy, not only diagnosis, but also biopsy can be done to confirm and to brush the cream-like plaque.²⁵ pH-meter is used to check the reflux whether it is acid, weak acid, or non-acid. From manometry, or nowadays used is multichannel impedance manometry, we can find the pressure change during relaxation or during a bolus passes through the esophagus. By means of both pH-meter and manometry, we can evaluate the motility of esophagus.²⁶

The first and the foremost in the therapeutic management of esophageal manifestation in diabetic patients is good glycemic control. By maintaining good glycemic control, complaints such as heartburn and dysphagia can be improved. For reflux disease, prokinetics and proton pump inhibitors can be applied.²⁷ Candida esophagitis is managed by administering antifungal agent such as azole groups, if the complaint does not get better after consumption of antifungal, further endoscopies might be needed. Good glycemic control and rational antibiotic treatment will reduce the recurrent candida infection risk.^{13,25} Pill-induced esophagitis is another type of esophagitis which is preventable by suggesting patients drink right after taking medicine.¹⁰

Manifestation on Gaster

Manifestation on gaster is the most frequent complication of diabetes mellitus in the gastrointestinal tract, which is gastroparesis. Gastroparesis is the retention of gastric contents or deceleration of gastric emptying without physical obstruction.²⁸ Symptom from gastroparesis varies from early satiety, burping, heartburn, persistent nausea, paroxysmal vomiting, even decrease of

body weight. However, these complaints can be overlapping with metabolic impairment, drugs adverse effect, or other diabetic complications.⁹ Diabetic gastroparesis could affect the glycemic control leading to nutritional disorders and repeated hospitalization.

Gastroparesis is one complication with big effect to the glycemic control of diabetic patients.³ Deceleration of gastric emptying will affect patients undergoing treatment with an oral hypoglycemic agent or exogenous insulin. Slower gastric emptying will slow down absorption of the oral hypoglycemic agent, which lead to poor glycemic control. On the other hand, patients with exogenous insulin will encounter hypoglycemic episode from abruptness of transportation in the gastrointestinal tract, so that absorption of consumed food is not enough to balance out administered insulin.^{3,29} Mismatch in these two methods of treatment will result in long-term poor glycemic control, also recurrent exacerbation of worsening complaints, leading to nutritional disorders and repetitive hospitalizations.³⁰

Diabetic gastroparesis usually appears in chronic diabetic patients with some risk factor such as other microangiopathy complications, neuropathy and nephropathy.³ Incidence of diabetic gastroparesis is higher in the female group, though the cause of such thing has not been found.^{21,31} Other risk factor is obesity, poor glycemic control, duration of diabetes for more than 10 years, also the existence of other complications.^{29,31,32} From anatomy and physiology, in diabetic gastroparesis, there is a change from the loss of the migration motor complex, dull gastric antrum contraction, and increasing of gastric pyloric spasm.²⁸ Other changing factors are such as neural impairment containing nitrite oxide inhibitors, loss of ICC in gaster, fibrosis of gastric smooth muscle, and abnormal macrophage infiltration.^{15,33} Neurohormonal factors such as glucagon-like peptide 1 and apolipoprotein E deficiency also prompt gastroparesis, so that drugs like GLP-1 agonist needs to be reconsidered in diabetic gastroparesis patients.³⁴

Management

First, history approach including the symptoms of gastroparesis to its complications, duration of diabetes, and other cause of gastroparesis aside from diabetes.¹⁰ In physical examination, neuropathy, distended epigastrium, and succussion 1-hour postprandial might be found.³² Other metabolic tests to exclude including ketoacidosis, uremia, hypocalcemia, hypothyroid, complete blood test for infection or immunologic disorders, amylase test, and pregnancy test.^{13,29} Another further examination is upper gastrointestinal endoscopy to rule out gastric outlet obstruction. If obstruction was not found, gastroparesis can be confirmed by nuclear scintigraphy or endoscopy.

Endoscopy can suspect diabetic gastroparesis if food is found after 12-hours fasting.¹³ Scintigraphy test is considered as the gold standard to diagnose gastroparesis by using Technetium TC-99M sulfur colloid which binds to food.³⁵ This examination starts with the patient ingesting ingest low-fat egg-white meal and then undergoing scintigraphy measurement once every 4 hours. Diagnosis of gastroparesis is confirmed if there is gastric retention >10%. Based on American Neurogastroenterology and Motility, another way to perform the examination is by using 2 slices of bread and 2 eggs labeled with technetium and will be measured 1, 2, and 4 hours postprandial by scintigraphy. Diagnosis can be established if retention is found >90% on the first hour, 60% on the second hour and >10% on the fourth hour.³⁶ Other examinations such as pH measurement, temperature and pressure of gaster, breath test, and electrogastrogram are radiation free, unlike scintigraphy. However, they are less accepted by physicians as they are considered experimental and have problematic sensitivity and specificity.^{37,38}

Management of diabetic gastroparesis starts from controlling blood glucose level and other exacerbating factors, followed by pharmacological therapy, or surgical therapy.¹⁰ Maintaining glycemic control is the most important principle in treating gastroparesis by improving symptoms, as well as preventing recurrence of gastroparesis. Other exacerbating factors such as electrolyte imbalance and

dehydration also need to be corrected.⁹ The next approach is diet modification, including avoiding things that can decelerate gastric emptying like alcohol, cigarettes, fatty food, and non-digestible fibers such as vegetables and fruits.⁹ Patients undergoing diet modification should be suggested to consume a low-fat diet in small portions more frequently. If this diet modification does not improve, then liquid based nutrition should be considered.³⁹

If glycemic control and diet modification do not suffice, the help of pharmacological therapy is needed. Metoclopramide is a commonly used drug, which act centrally in the chemoreceptor trigger zone. Metoclopramide has been approved as a gastroparesis therapy and known to improve acute complaint for several weeks, but its long-term effects are not clear yet, tardive dyskinesia and extrapyramidal syndrome are some of the noticeable adverse effects.⁴⁰ Domperidone is still used in several countries. Working as type 2 receptor antagonist, domperidone is also effective in an acute case with nausea, vomiting, and bloated feeling. One of its adverse effects is QTc interval elongation which can cause cardiac arrhythmia.⁴¹ Erythromycin, considered as one of the best drugs of choice, is reported to be the most effective drug to improve severe complaints if administrated intravenously with high dose followed orally for weeks. A well-known adverse effect for erythromycin is nausea and vomiting.⁴² Cisapride, working as 5-HT₄ agonist which accelerates gastric emptying and stimulates antrum contraction and improve antroduodenal coordination. Due to its adverse effect to heart, this drug has been withdrawn in several countries. But other 5-HT₄ agonist groups has not been proven effective.⁴³ Newest drug that can be used is ghrelin, a peptide produced by gastric fundal mucous and pancreas, working in gastric motility regulation. The use of ghrelin agonist, TZP 101, is still experimental but proven to improve symptoms in diabetic gastroparesis patients.^{44,45}

If pharmacological therapy does not indicate results, then endoscopy therapy or surgical therapy might be needed. Endoscopic therapy is performed by injecting botulinum toxin to pylorus so that pylorus undergo paralysis and

improve the complaint of gastroparesis, though this method has not been proven significant.⁴⁶ Electric gastric stimulator implant has been used for more than 10 years and has shown to improve nausea and vomiting up to 80% patients, but some has been withdrawn due to the infection.⁴⁷ Surgical approaches includes pyloroplasty, gastrectomy, or jejunostomy to improve complaints like nausea, vomiting, and bloating even though the results post-surgical is not clearly reported.⁴⁸ However, endoscopic or surgical therapy still need to be followed with good glycemic control to maintain well-functioning gastric emptying.

Manifestation on Intestines

The manifestation of diabetic complications on intestines are diarrhea, constipation, and fecal incontinence, especially during night time.⁴⁹ Apart from upper gastrointestinal tract complaints, enteropathy could also be resulted by diseases other than diabetes such as celiac disease, lactose intolerance, drug reaction, and pancreas malfunction so that diabetic enteropathy complication needs a different approach and comprehensive management.^{20,50}

The underlying pathophysiology of enteropathy complication is neuropathy and hyperglycemia. Constipation is the most common symptoms with 60% of long-term diabetic patients. Constipation is mainly occurred by the damaged myenteric nerve plexus, loss of ICC, and fibrosis of intestinal mucous leading to reduced motility of the intestines.¹⁰ Decelerated intestine motility cause stasis which leads to small intestine bacterial overgrowth (SIBO). SIBO will cause diarrhea on patients with diabetes mellitus and enteropathy complication. Diarrhea covers 20% of diabetes mellitus patients.⁵¹ Diarrhea can also be generated by adverse effect of hypoglycemic agents such as metformin, alpha-glucosidase inhibitor, glucagon-like peptide (GLP)-1 agonist, and dipeptidyl peptidase-4 (DPP4) inhibitor.^{52,53} Enteropathy diarrhea on diabetes mellitus patients is often followed by fecal incontinence due to dysfunction of external and internal anal sphincter, and rectum contraction. This dysfunction is related to the hyperglycemic condition which has been proven to inhibit the function of anal sphincter and

reduce the compliance of rectum by elevation of oxidative stress like nitrite oxide, therefore the fecal incontinence.^{54,55}

Patients suffering under diabetic enteropathy particularly diarrhea and constipation should be ruled out of other possible causative agents notably induced hypoglycemic agents. Hypoglycemic agents should be stopped, dose readjusted, or replaced by other gastrointestinal tract friendlier agents.⁵⁶ If enteropathy symptoms are still persistent, further examination including endoscopy, fecal culture, or lactose-free management should be considered to rule out lactose intolerance, or ceasing diarrhea inducing drugs.¹⁰ One of radiologic examination to understand enteropathy particularly constipation is by using radiopaque marker to measure the colon transit time.⁵⁷ For diarrhea, jejunal aspiration is the gold standard to find out whether or not SIBO is exist, which can also be confirmed by breath test. However, these two examination has their limitation in sensitivity and specificity because of fully contaminated gastrointestinal tract.⁵⁸ Manometry can be used for fecal incontinence, by which can confirm diagnosis by measuring decreased anal sphincter tone.²⁰

Management

The most important thing in management of suspected diabetic enteropathy is to evaluate dehydration status and electrolyte imbalance because patient might need to be treated as inpatient. Just like in the gastroparesis, the initial approach is to reach good glycemic control and diet management, which is low-fat in a frequent small portion. If this approach fails, then additional pharmacological therapy is needed.²⁰ For diarrhea, opioid group antidiarrheal drugs can be administered with caution of toxic megacolon and worsen bacterial overgrowth. For SIBO condition problem, selective antibiotic management will be needed. Rifaximin is the best agent based on researches for this disorder, selectively work in gastrointestinal tract, low resistance, and improve complaints for 33% to 99% of patients.⁵⁹ For uncontrolled diabetic patients, somatostatin group such as octreotide and lanreotide has been reported to improve symptoms.⁵⁸

Complaint of constipation can be managed

by sufficient hydration, high-fiber meals, and routine physical activities. On worse case scenario, osmotic laxative or lactulose will help. Constipation is often followed by abdominal pain. In this case, pain relief from antidepressant tricyclic or tetracyclic group can be given.²⁹ Fecal incontinence often improve by itself within good glycemic control, but if the symptom persists, loperamide can be administered.⁶⁰

PROGNOSIS

In spite of the various therapy on esophagus, gaster, and intestines, those therapies often hard to achieve and manifestations keep recurring. This is mainly due to poor glycemic control and aggravated by complications such as dehydration, electrolyte imbalance, and malnutrition, which intensify the morbidity of diabetes mellitus patients. Therefore, we need to improve the general condition of the patients and also maintain good glycemic control aside from resolving problems based on symptoms and manifestations and to prevent the recurring complications.

CONCLUSION

Diabetic gastroenteropathy is one of major morbidity and complication in diabetes mellitus patients, especially long-term patients or patients with neuropathy. Diagnosis of diabetic gastroenteropathy needs to be well observed and it is also important to rule out other possibilities. Management of the complications also needs a meticulous attention because aside from resolving those complaints, we also need to maintain good glycemic control. Furthermore, research for alternative therapies for diabetic gastroenteropathy, which are better in improving symptoms with fewer adverse effects, is highly recommended.

ACKNOWLEDGMENTS

We would like to thank the Dean of Faculty of Medicine, Airlangga University, and the Director of Dr. Soetomo General Hospital.

REFERENCES

1. Yarandi SS, Srinivasan S. Diabetic gastrointestinal motility disorders and the role of enteric nervous system: Current status and future directions. *Neurogastroenterology and Motility*. 2014; 26(5):611-24. <https://www.ncbi.nlm.nih.gov/pmc/articles/PMC4104990/>
2. Rodrigues ML, Motta ME. Mechanisms and factors associated with gastrointestinal symptoms in patients with diabetes mellitus. *J de Pediatría*. 2012;88(1):17-24. <https://www.ncbi.nlm.nih.gov/pubmed/22344626>
3. Camilleri M. Clinical practice. Diabetic gastroparesis. *New Engl J Med*. 2007;356(8):820-9. <https://www.ncbi.nlm.nih.gov/pubmed/17314341>.
4. International Diabetes Federation. IDF diabetes atlas. 8th ed. Brussel: International Diabetes Federation; 2017.
5. Maleki D. Gastrointestinal tract symptoms among persons with diabetes mellitus in the community. *JAMA*. 2000;160(18):2808-16. <https://www.ncbi.nlm.nih.gov/pubmed/11025791>.
6. Gustaffson RJ. Esophageal dysmotility is more common than gastroparesis in diabetes mellitus and is associated with retinopathy. *Rev Diab Studies*. 2011; 8(2):268–75. <https://www.ncbi.nlm.nih.gov/pmc/articles/PMC3280012/>.
7. Wang X. Increased prevalence of symptoms of gastroesophageal reflux diseases in type 2 diabetics with neuropathy. *World J Gastroenterol*. 2008;14(5): 709-12. <https://www.ncbi.nlm.nih.gov/pmc/articles/PMC2683996/>.
8. Foris LA, Bhimji SS. Diabetic gastroparesis. Grenada: Stat Pearls Publishing; 2017.
9. Aljarallah BM. Management of diabetic gastroparesis. *Saudi J Gastroenterol*. 2011;17(2):97-104. <https://www.ncbi.nlm.nih.gov/pmc/articles/PMC3099072/>.
10. Krishnan B. Gastrointestinal complications of diabetes mellitus. *World J Diab*. 2013;4(3):51-63. <https://www.ncbi.nlm.nih.gov/pmc/articles/PMC3680624/>.
11. Khoshbaten M. Gastrointestinal signs and symptoms among persons with diabetes mellitus. *Gastroenterology and Hepatology from Bed to Bench*. 2011;4(4):219-23. <https://www.ncbi.nlm.nih.gov/pmc/articles/PMC4017431/>.
12. Callaghan BC. Enhanced glucose control for preventing and treating diabetic neuropathy. *Cochrane database systematic review*. 2012;6: CD007543. <https://www.ncbi.nlm.nih.gov/pmc/articles/PMC4048127/>.
13. Podolsky DK. Yamada's textbook of gastroenterology. Chicester: John Wiley & Sons, Ltd; 2016.
14. Ordog T, Hayashi Y, Gibbons SJ. Cellular pathogenesis of diabetic gastroenteropathy. *Minerva Gastroenterol Dietol J*. 2009;55(3):315-343. <https://www.ncbi.nlm.nih.gov/pmc/articles/PMC2854169/>.

15. Ordog T. Interstitial cells of Cajal in diabetic gastroenteropathy. *Neurogastroenterol Motility*. 2008;20(1):8-18. <https://www.ncbi.nlm.nih.gov/pubmed/18173559>.
16. Lee HT. The mechanism and spread of pacemaker activity through myenteric interstitial cells of Cajal in human small intestine. *Gastroenterol*. 2007;132(5):1852-965. <https://www.ncbi.nlm.nih.gov/pubmed/17484879>.
17. Lin HZ. Association of the status of interstitial cells of Cajal and electrogastrogram parameters, gastric emptying and symptoms in patients with gastroparesis. *Neurogastroenterol Motility*. 2010;22(1):56-61. <https://www.ncbi.nlm.nih.gov/pubmed/19614868>.
18. Camilleri M. Gastrointestinal problems in diabetes. *Endocrinol Metab Clin North Am*. 1996;25(2):361-78. <https://www.ncbi.nlm.nih.gov/pubmed/8799704>.
19. Bytzer P. GI symptoms in diabetes mellitus are associated with both poor glycemic control and diabetic complications. *Am J Gastroenterol*. 2002;97(3):604-11. <https://www.ncbi.nlm.nih.gov/pubmed/11922554>.
20. Maisey A. A practical approach to gastrointestinal complications of diabetes. *Diab Ther*. 2016;7(3):379-86. <https://www.ncbi.nlm.nih.gov/pmc/articles/PMC5014788/>.
21. Rayner CK. Relationships of upper gastrointestinal motor and sensory function with glycemic control. *Diab Care*. 2001;24(2):371-81. <https://www.ncbi.nlm.nih.gov/pubmed/11213895>.
22. Saeed A. Fungal esophagitis in a child with insulin dependent diabetes mellitus. *J Coll Physic Surg Pakistan*. 2016;26(8):712-13. <https://www.ncbi.nlm.nih.gov/pubmed/27539771>
23. Frøkjær JB. Impaired contractility and remodeling of the upper gastrointestinal tract in diabetes mellitus type-1. *World J Gastroenterol*. 2007;13(36):4881-90. <https://www.ncbi.nlm.nih.gov/pmc/articles/PMC4611767/>.
24. Lee SD. Gastroesophageal reflux disease in type 2 diabetes mellitus with or without peripheral neuropathy. *Neurogastroenterol Motility*. 2011;17(3):274-8. <https://www.ncbi.nlm.nih.gov/pmc/articles/PMC3155063/>.
25. Wilcox CM. Infectious esophagitis. *Gastroenterol Hepatol*. 2006;2(8):567-568. <https://www.ncbi.nlm.nih.gov/pmc/articles/PMC5350250/>.
26. Vandenplas Y. *Gastroesophageal reflux in children*. Brussel: Springer International Publishing; 2017.
27. Chang CT. Improvement of esophageal and gastric motility after 2-week treatment of oral erythromycin in patients with non-insulin-dependent diabetes mellitus. *J Diab Complications*. 2003;17(3):141-4. <https://www.ncbi.nlm.nih.gov/pubmed/12738398>.
28. Hasler W. Gastroparesis. *Curr Opin Gastroenterol*. 2012;28(6):621-8. <https://www.ncbi.nlm.nih.gov/pubmed/23041675>
29. Parkman HP, Fass R, Foxx-Orenstein AE. Treatment of patients with diabetic gastroparesis. *Gastroenterol Hepatol*. 2010;6 (6 Suppl 9):1-16. <https://www.ncbi.nlm.nih.gov/pmc/articles/PMC2920593/>.
30. Parkman HP. Similarities and differences between diabetic and idiopathic gastroparesis. *Clin Gastroenterol Hepatol*. 2011;9(12):1056-134. <https://www.ncbi.nlm.nih.gov/pmc/articles/PMC3499102/>.
31. Almogbel RA. Prevalence and risk factors of gastroparesis-related symptoms among patients with type 2 diabetes. *Int J Health Sci*. 2016;10(3):397-404. <https://www.ncbi.nlm.nih.gov/pmc/articles/PMC5003583/>.
32. Boaz M. Obesity and symptoms suggestive of gastroparesis in patients with type 2 diabetes and neuropathy. *J Diab Compl*. 2011;25(5):325-8. <https://www.ncbi.nlm.nih.gov/pubmed/21813291>.
33. Grover M. Cellular changes in diabetic and idiopathic gastroparesis. *Gastroenterol*. 2011;140(5):1575-1585. <https://www.ncbi.nlm.nih.gov/pmc/articles/PMC3081914/>.
34. Ravella K, Yang H, Gangula PRR. Impairment of gastric nitrergic and NRF2 system in apolipoprotein E knockout mice. *Dig Dis Sci*. 2012;57(6):1504-9. <https://www.ncbi.nlm.nih.gov/pmc/articles/PMC3677538/>.
35. Tougas G. Standardization of a simplified scintigraphic methodology for the assessment of gastric emptying in a multicenter setting. *Am J Gastroenterol*. 2000;95(1):78-86. <https://www.ncbi.nlm.nih.gov/pubmed/10638563>.
36. Abell T. Consensus recommendations for gastric emptying scintigraphy: a joint report of the American Neurogastroenterology and Motility Society and the Society of Nuclear Medicine. *Am J Gastroenterol*. 2008;103(3):753-63. <https://www.ncbi.nlm.nih.gov/pubmed/18028513>.
37. Perri F et al. (13)C-octanoic acid breath test (OBT) with a new test meal (EXPIROGer): Toward standardization for testing gastric emptying of solids. *Digestive and Liver Disease*. 2010;42(8): 549-553. <https://www.ncbi.nlm.nih.gov/pubmed/20116352>
38. Lee A, Wilding G, Kuo B. Variable abnormal physiological motility in the proximal upper gastrointestinal tract in gastroparesis. *Neurogastroenterol Motility*. 2012;24(7):652-e276. <https://www.ncbi.nlm.nih.gov/pmc/articles/PMC3376693/>.
39. Abrahamsson H. Treatment options for patients with severe gastroparesis. *Gut*. 2007;56(5):877-883. <https://www.ncbi.nlm.nih.gov/pmc/articles/PMC1954884/>.
40. Lee A, Kuo B. Metoclopramide in the treatment of diabetic gastroparesis. *Expert Rev Endocrinol Metabolism*. 2010;5(5):653-662. <https://www.ncbi.nlm.nih.gov/pmc/articles/PMC3027056/>.
41. Schey R. Domperidone to treat symptoms of gastroparesis: Benefits and side effects from a large single-center cohort. *Digest Dis Sci*. 2016;61(12):3545-51. <https://www.ncbi.nlm.nih.gov/pubmed/27530760>.

42. Maganti K, Onyemere K, Jones MP. Oral erythromycin and symptomatic relief of gastroparesis: a systematic review. *Am J Gastroenterol.* 2003;98(2):259-63. <https://www.ncbi.nlm.nih.gov/pubmed/12591038>.
43. Hasler WL. Gastroparesis-current concepts and considerations. *Medscape J Med.* 2008;10(1):16. <https://www.ncbi.nlm.nih.gov/pmc/articles/PMC2258461/>.
44. Mondal A. Coordination of motilin and ghrelin regulates the migrating motor complex of gastrointestinal motility in *Suncus murinus*. *Am J Physiol. Gastrointest Liv Physiol.* 2012;302(10):G1207-15. <https://www.ncbi.nlm.nih.gov/pubmed/22383491>.
45. Wo JM. Randomised clinical trial: ghrelin agonist TZP-101 relieves gastroparesis associated with severe nausea and vomiting--randomised clinical study subset data. *Alimentary Pharmacology & Therapeutic.* 2011;33(6):679-88. <https://www.ncbi.nlm.nih.gov/pubmed/21214610>.
46. Friedenberg FK. Botulinum toxin A for the treatment of delayed gastric emptying. *Am J Gastroenterol.* 2008;103(2):416-23. <https://www.ncbi.nlm.nih.gov/pubmed/18070232>.
47. McCallum RW. Gastric electrical stimulation improves outcomes of patients with gastroparesis for up to 10 years. *Clin Gastroenterol Hepatol.* 2011;9(4):314-9. <https://www.ncbi.nlm.nih.gov/pubmed/21185396>.
48. Jones MP, Maganti K. A systematic review of surgical therapy for gastroparesis. *Am J Gastroenterol.* 2003; 98(10):2122-9. <https://www.ncbi.nlm.nih.gov/pubmed/14572555>.
49. Chandrasekharan B. Colonic motor dysfunction in human diabetes is associated with enteric neuronal loss and increased oxidative stress. *Neurogastroenterol Motility.* 2011;23(2):131-26. <https://www.ncbi.nlm.nih.gov/pmc/articles/PMC3020997/>.
50. Noel RA. Increased risk of acute pancreatitis and biliary disease observed in patients with type 2 diabetes. *Diab Care.* 2009;32(5):834-8. <https://www.ncbi.nlm.nih.gov/pmc/articles/PMC2671118/>.
51. Ohlsson B. Oesophageal dysmotility, delayed gastric emptying and autonomic neuropathy correlate to disturbed glucose homeostasis. *Diabetologia.* 2006; 49(9):2010-4. <https://www.ncbi.nlm.nih.gov/pubmed/16832660>.
52. Lysy J, Israeli E, Goldin E. The prevalence of chronic diarrhea among diabetic patients. *Am J Gastroenterol.* 1999;94(8):2165-70. <https://www.ncbi.nlm.nih.gov/pubmed/10445544>.
53. Consoli A, Formoso G. Potential side effects to GLP-1 agonists: understanding their safety and tolerability. *Expert Opinion on Drug Safety.* 2015;14(2):207-18. <https://www.ncbi.nlm.nih.gov/pubmed/25496749>.
54. Russo A. Effects of acute hyperglycaemia on anorectal motor and sensory function in diabetes mellitus. *Diabetic Med.* 2004;21(2):176-82. <https://www.ncbi.nlm.nih.gov/pubmed/14984454>.
55. Fillmann HS. Diabetes mellitus and anal sphincter pressures: an experimental model in rats. *Dis Colon Rectum.* 2007;50(4):517-22. <https://www.ncbi.nlm.nih.gov/pubmed/17285232>.
56. Krentz AJ, Bailey CJ. Oral antidiabetic agents: current role in type 2 diabetes mellitus. *Drugs.* 2005;65(3):385-411. <https://www.ncbi.nlm.nih.gov/pubmed/15669880>.
57. Saberi H. Measurement of colonic transit time based on radio opaque markers in patients with chronic idiopathic constipation: A cross-sectional study. *Iranian Red Crescent Med J.* 2013;15(12):e16617. <https://www.ncbi.nlm.nih.gov/pmc/articles/PMC3955515/>.
58. Bures J. Small intestinal bacterial overgrowth syndrome. *World J Gastroenterol.* 2010;16(24):2978-90. <https://www.ncbi.nlm.nih.gov/pmc/articles/PMC2890937/>.
59. Pimentel M. Review of rifaximin as treatment for SIBO and IBS. *Expert Opin Invest Drug.* 2009;18(3):349-358. <https://www.ncbi.nlm.nih.gov/pubmed/19243285>.
60. Gatopoulou A, Papanas N, Maltezos E. Diabetic gastrointestinal autonomic neuropathy: current status and new achievements for everyday clinical practice. *Eur J Intern Med.* 2012;23(6):499-505. <https://www.ncbi.nlm.nih.gov/pubmed/22863425>.