

Transcatheter Closure of Post-operative Residual Ventricular Septal Defect Using a Patent Ductus Arteriosus Closure Device in an Adult: a Case Report

Mulyadi M. Djer¹, Nikmah S. Idris¹, Idrus Alwi², Ika P. Wijaya²

¹ Department of Pediatrics, Faculty of Medicine, Universitas Indonesia - Cipto Mangunkusumo Hospital, Jakarta, Indonesia.

² Department of Internal Medicine, Faculty of Medicine, Universitas Indonesia, Jakarta, Indonesia.

Correspondence mail:

Department of Pediatrics, Faculty of Medicine, Universitas Indonesia - Cipto Mangunkusumo Hospital. Jl. Diponegoro no. 71, Jakarta 10430, Indonesia. email: muldjer@yahoo.com; muldjer@gmail.com.

ABSTRAK

Penutupan ventricular septal defect (VSD) transkateter pada VSD perimembran dan VSD muskular saat ini sudah banyak dilakukan dan memiliki banyak keuntungan dibandingkan dengan operasi. Pada VSD residual pasca-operasi penyakit jantung bawaan (PJB) kompleks, tindakan ini masih merupakan tantangan karena kelainan anatomi yang kompleks, stabilitas alat yang kurang sehingga perlu kecermatan untuk memilih teknik dan alat yang tepat.

Makalah ini melaporkan tindakan penutupan VSD residual pasca-operasi Rastelli pada pasien double outlet right ventricle (DORV), sub-aortic VSD, severe infundibulum pulmonary stenosis (PS) dan single arteri koroner. Pasien sudah menjalani empat kali operasi, namun masih ada VSD residual yang signifikan sehingga pasien mengalami gagal jantung yang tidak dapat dikontrol dengan obat. Pertama kali VSD residual ditutup menggunakan alat penutup VSD, namun setelah alat direlease, alat terlepas dan mengalami embolisasi ke aorta, alat dapat diambil kembali dengan snare. Kemudian VSD ditutup menggunakan alat penutup patent ductus arteriosus (PDA). Pasca-penutupan VSD, posisi alat stabil. Setelah tindakan, kondisi klinis membaik dan pasien dapat dipulangkan. Berdasarkan pengalaman ini, kami menyimpulkan bahwa metode transkateter menggunakan alat penutup PDA cukup efektif untuk menutup VSD residual pada PJB kompleks dengan hasil yang cukup baik.

Kata kunci: VSD residual, alat penutup PDA, penutupan transkateter, gagal jantung, Rastelli.

ABSTRACT

Transcatheter closure of perimembranous and muscular ventricular septal defect (VSD) has been performed widely and it has more advantages compare to surgery. However, transcatheter closure of residual VSD post operation of complex congenital heart disease is still challenging because of the complexity of anatomy and concern about device stability, so the operator should meticulously choose the most appropriate technique and device.

We would like to report a case of transcatheter closure of residual VSD post Rastelli operation in a patient with double outlet right ventricle (DORV), sub-aortic VSD, severe infundibulum pulmonary stenosis (PS) and single coronary artery. The patient had undergone operations for four times, but he still had intractable heart failure that did not response to medications. On the first attempt. we closed the VSD using a VSD occluder, unfortunately the device embolized into the descending aorta, but fortunately we was able to snare it out. Then we decided to close the VSD using a patent ductus arteriosus (PDA occluder). On transesophageal echocardiography (TEE) and angiography evaluation, the device position was stable. Post transcatheter VSD closure, the patient clinical

condition improved significantly and he could finally be discharged after a long post-surgery hospitalization. Based on this experience we concluded that the transcatheter closure of residual VSD in complex CHD using PDA occluder could be an effective alternative treatment.

Key words: residual VSD, PDA occluder, transcatheter closure, heart failure, Rastelli.

INTRODUCTION

Transcatheter closure of post-operative residual ventricular septal defect (VSD) in complex congenital heart disease (CHD) is a challenge for interventional cardiologists. Challenges may include but are not limited to the complexity of the procedure, the difficulty in obtaining catheter access and pathways, the accuracy in choosing the device, and the stability of the device due to a high risk of embolization.^{1,2}

Residual VSD after a cardiac surgery of complex CHD is quite common. It occurs because the surgery is performed while the heart is beating, so that the surgeon may not be able to ensure a perfect closure.³⁻⁵ Evaluation can only be done with transesophageal echocardiography when the patient is already off-bypass,⁶ thus, if a complete closure was not achieved, the patient must undergo re-operation. With current advances in cardiac interventions, the need for re-operation can be minimized.⁷⁻¹³

CASE ILLUSTRATION

Our patient was a 22-year-old male with body weight of 55 kg, referred from Bali, with a chief complaint of cyanosis since birth. On physical examination, cyanosis was seen in the lips and tongue, but no dyspnea was observed. His first heart sound was normal and the second heart sound was single. The grade 3 out of 6 systolic ejection murmur was best heard at the second intercostal space of the left parasternal line. Respiratory sounds were vesicular with no rhonchi. The abdomen was flat with good turgor and no hepatomegaly. Clubbed fingers were found on the extremities. Laboratory examination showed a hemoglobin level of 23.1 g/dL, hematocrit 71.1%, leukocytes 9,210/uL, and platelets 420,000/uL. Right QRS axis and right ventricular hypertrophy were found on electrocardiogram, while the chest x-ray showed right ventricular hypertrophy with concave

pulmonary segment and decreased pulmonary blood flow. Echocardiography showed double outlet right ventricle (DORV), sub-aortic VSD and severe infundibulum pulmonary stenosis. On cardiac catheterization, we identified a single sub-aortic VSD and both main arteries arising from the right ventricle. The patient was scheduled for total surgical correction, consisting of VSD closure with left ventricle-aorta tunneling and right ventricular outflow tract (RVOT) repair with transannular patch.

During the operation, the surgeon found that the patient had only a single coronary artery, with the right coronary artery crossing in front of the RVOT, making the resection and transannular patching was not feasible to perform. So, the surgeon decided to perform a Rastelli procedure with implantation of a conduit to connect the right ventricle to the pulmonary artery. The VSD was closed by creating an intracardiac tunnel connecting the left ventricle and the aorta.

During post-operative care, the patient developed symptomatic heart failure. Echocardiography revealed significant residual VSDs. The patient still experienced dyspnea, recurrent pleural effusion, and persistent heart failures, which did not respond to the anti-heart failure drugs, including furosemide (20 mg twice daily), spironolactone (25 mg twice daily), captopril (12.5 mg twice daily), and digoxin (0.125 mg twice daily). Therefore, the patient needed re-operation to close the residual VSDs. Re-operation was performed twice, but residual VSDs were still found and heart failure persisted. Based on a discussion with physicians and parents, he underwent a catheterization procedure to close the residual VSDs.

On catheterization, aortic pressure was 78/46 mmHg (mean pressure 57 mmHg) and pulmonary artery pressure was 30/15 mmHg (mean pressure 24 mmHg). Multiple residual VSDs were identified on left ventricle

angiography. We decided to close the VSD with a 10 mm symmetrical perimembranous device (Lifetech®). A Terumo® guide wire and Judkin Right® (JR) catheter were used in this procedure to locate and cross the VSD from the left ventricle to the right ventricle. Several attempts were made before successfully crossing the VSD. After the wire crossed the VSD, several attempts were made to engage it into the right atrium and then to the vena cava, but these attempts failed. We then advanced the wire into the pulmonary artery, after which it was snared and pulled out of the inferior caval vein to create an artery-venous loop.

Over the guide wire, a delivery catheter was introduced into the inferior caval vein and advanced until its tip reached the ascending aorta. The JR catheter and guide wire were manipulated in such a way that it formed a loop, which slid into the left ventricle, so that the tip of the delivery catheter was positioned in the left ventricle. After the delivery catheter tip was positioned in the left ventricle, the guide wire was withdrawn. A VSD closure device which had been screwed into the tip of a delivery cable, was compressed inside a loading catheter, which then was introduced under the delivery catheter. The device, attached by screw to the delivery cable, was advanced until it reached the left ventricle. The left disk of the device was deployed first, then the whole system was pulled out until the left disk touched the ventricular septum. Then the right disk was opened in the right ventricle by pulling out the delivery system. After deployment, angiography was performed several times to check the device position before release, showing that the device fit stably across the defect. However, after release, the device embolized into the ascending aorta and then to the descending part near the iliac bifurcation. We successfully snared and withdrew the device. By way of femoral arterial angiography, no damage to the right iliac artery was observed.

Using the same technique as described above, we re-crossed the VSD using a JR catheter and a Terumo® guide wire. We decided to close the VSD with a PDA closure device, because this device is longer and quite stable to engage to the VSD. Using the same technique, the delivery

catheter over the guide wire was advanced until its tip reached the ascending aorta, then the guide wire was pulled out. The PDA closure device was attached by screw to the tip of the delivery cable, compressed inside a loading catheter and introduced into the delivery catheter. Initially, the retention disk was deployed in the ascending aorta, followed by pulling down the whole system until the retention disk was positioned below the aortic valve. Subsequently, the whole system was slowly pulled again until the side of the device touched the ventricular septum, followed by pulling the delivery catheter to open the body of the device. Transesophageal echocardiography (TEE) and angiography were performed to check the device position and stability, revealing good results. Then we released the device from the delivery cable, after which it still sat nicely across the defect. When the angiogram was repeated, the position was found to be stable, but other residual VSDs were identified. Our attempt to cross the other residual VSDs using a guide wire and a JR catheter was unsuccessful. Finally, we decided to end the procedure because we were concerned that further manipulation using the catheter would dislodge the implanted device. Moreover, after the biggest residual VSD was successfully closed, the pressure of the right ventricle decreased by half immediately afterwards, so that a further attempt to close other residual VSDs was considered unnecessary.

After the procedure, the patient was transferred directly to the ward without need for ICU care. He was clinically improved. His chest x-ray showed decreased cardiomegaly and no more pericardial effusion. The patient was discharged one week after the transcatheter closure procedure in good condition after having been hospitalized for almost 3 months.

DISCUSSION

Although cardiac interventions have developed in the last two decades, surgery remains to be the only definitive treatment for complex CHD.³⁻⁵ This patient had a complex CHD, consisting of DORV, subaortic VSD, and severe pulmonary stenosis. The definitive therapy for this kind of heart lesion is a total surgical correction to close the VSD with

tunneling from the left ventricle (LV) to the aorta, resecting and enlarging the RVOT with transannular patching.³⁻⁵ Because the patient had only one coronary artery, in which the branch of the right coronary artery crossed in front of the RVOT, a resection to enlarge the RVOT was not possible. For this reason, we decided to implant a conduit to connect the right ventricle to the pulmonary artery.

Post-operatively the symptoms of heart failure persisted because the residual VSDs did not respond to anti-heart failure drugs. VSD closure with LV-aorta tunneling frequently results in residual VSDs because of the difficulty in part of the VSD being located beneath the aortic valve region. Since the procedure is done while the heart is not beating, the surgeon cannot ensure a complete VSD closure. The confirmation can only be done when the heart is beating again, using TEE.⁶ Another possible cause for residual VSDs in our patient was the loss of stitches between the patch and the heart tissue. The patient's persistent heart failure symptoms necessitated closure of the residual VSDs. The stitches were found to be loose during the second re-operation to close the residual VSDs, such that the surgeon had to do re-hecting. Subsequently, we still found significant residual VSDs causing persistent heart failure. Unfortunately, a third re-operation still failed to close the VSDs.

Surgery had been the only definitive way to treat CHD before interventional cardiology became popular. Although surgery is effective in most cases, it is also very invasive because the movement of the heart must be stopped using a cardioplegic drug during the operation and blood circulation must be maintained by the heart-lung machine. The use of this machine is risky because the blood has to flow through an artificial vessel without an endothelial layer. Blood that comes into contact with this artificial vessel will be destroyed, releasing inflammatory mediators which can result in a systemic inflammation response syndrome (SIRS).³⁻⁵ Therefore, VSD closure by operation carries a high risk. This patient still had residual VSDs even though he had undergone three operations. Performing a fourth operation did not seem to be a good option, since it was a burden for the patient and his

family and had a risk of a life-threatening event.

Cardiological intervention was developed to deal with this kind of situation. It offers a technique to cure CHD without surgery, which is often effective, less invasive, and also poses a lower risk compared to surgery. Cardiac intervention is currently the treatment of choice for certain types of non-cyanotic CHD, such as VSD, ASD, PDA, and pulmonary valve stenosis or aortic stenosis.⁶⁻¹³ Cardiac intervention techniques have been reported to be effective for closing residual VSDs found after a complex CHD surgery.^{1,2} These findings encouraged us to perform the transcatheter closure of VSDs in our patient.

Transcatheter closure of residual VSDs after a complex CHD operation is actually more difficult because of the complexity of the procedure, the non-ideal defect shape, heart tissue fragility and poor device stability, rendering a high risk of embolization. It is, therefore, crucial to choose the appropriate device and size.^{1,2} Initially, a 10-mm symmetrical VSD perimembranous closure device was used in our patient. Although the stability of the device had been checked before it was released, it embolized to the aorta. Fortunately, the device was successfully withdrawn by a snare. One of the advantages of the transcatheter procedure is that the device can be pulled back if there is an embolization without resulting in significant damage to the vessel.

On the second attempt, we used a 12-mm PDA closure device to close the residual VSD. Some reports stated that a PDA closure device can be used to close residual VSDs because this device has a relatively longer size.¹ After the residual VSD was closed in our patient, the right ventricular systolic pressure decreased by half. After the device had been released, it remained stable and did not embolize (**Figure 1**). The device looked stable on post-procedure serial angiogram, however, there were still many small residual shunt VSDs from other VSDs. We tried to cross the other residual VSDs, but we were unsuccessful and finally we decided to end the procedure considering the risk of dislodging the implanted device. Fortunately, the patient significantly improved clinically after his biggest

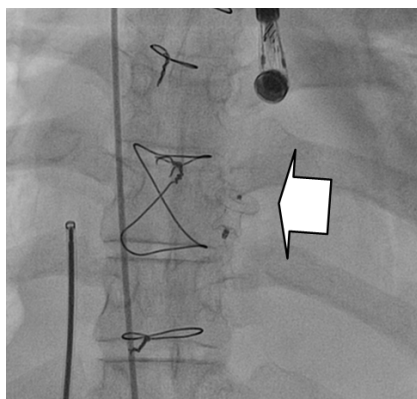


Figure 1. PDA closure device looked stable on the VSD site (arrow sign).

residual VSD was closed with the PDA closure device. The patient was finally discharged after prolonged hospitalization prior to the interventions. Previous reviews also reported good success rates of transcatheter closure of VSD using a PDA closure device.^{1,2}

CONCLUSION

Transcatheter closure of post-operative residual VSD using a PDA closure device can be effective and serve as a good alternative for re-operation.

ACKNOWLEDGMENTS

We would like to thank Dr. Krishna Kumar, from India, who assisted in performing the intervention.

REFERENCES

1. Vaidyanathan B, Kannan BR, Kumar RK. Device closure of residual ventricular septal defect after repair of tetralogy of fallot using amplatzer duct occluder. *Indian Heart J.* 2005;57:164-6.
2. Dua JS, Carminati M, Lucenta M, et al. Transcatheter closure of postsurgical residual ventricular septal defects: early and mid-term results. *Catheter Cardiovasc Interv.* 2010;75:246-55.
3. Vinocur JM, Menk JS, Connett J, Moller JH, Kochiilas LK. Surgical volume and center effects on mortality after pediatric cardiac surgery: 25-year North American experience from a multi-institutional registry. *Pediatr Cardiol.* 2013 [E-pub ahead of print]. Available from: <http://www.ncbi.nlm.nih.gov/pubmed/23377381>
4. Guerra GG, Robertson CMT, Alton GW, et al. Quality of life 4 years after complex heart surgery in infancy. *J Thorac Cardiovasc Surg.* 2013;145:482-8.
5. Awori MN, Leong W, Artrip JH, O'Donnell C. Tetralogy of Fallot repair: optimal z-score use for transannular patch insertion. *Eur J Cardiothorac Surg.* 2013;14:483-6.
6. Perk G, Kronzon. Interventional echocardiography in structural heart disease. *Curr Cardiol Rev.* 2013;15:338.
7. Akagi T. Catheter intervention for adult patients with congenital heart disease. *J Cardiol.* 2012;60:151-9.
8. Crystal MA, Ing FF. Pediatric interventional cardiology: 2009. *Curr Opin Pediatr.* 2010;22:567-72.
9. Giroud JM, Zahn EM, Ringewald J, Suh EJ. Innovation in interventional cardiology. *Cardiol Young.* 2009;19:43-7.
10. Hijazi ZM, Awad SM. Pediatric cardiac interventions. *J Am Coll Cardiol Intv.* 2008;1:603-11.
11. Vincent RN, Diehl HJ. Interventions in pediatric cardiac catheterization. *Crit Care Nurs Q.* 2002;25:37-47.
12. Hollinger I, Mitnacht A. Cardiac catheterization laboratory: catheterization, interventional cardiology, and ablation techniques for children. *Int Anesthesiol Clin.* 2009;47:63-99.
13. Mehta R, Lee KJ, Chaturvedi R, Benson L. Complications of pediatric cardiac catheterization: a review in the current era. *Catheter Cardiovasc Interv.* 2008;72:278-85.