

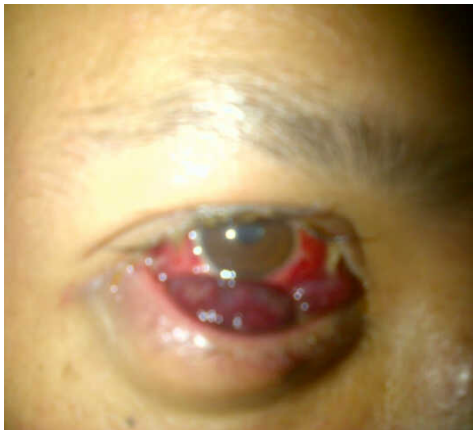
## Kaposi Sarcoma of the Eye in an HIV Patient Well-responded to HAART

*Erni J. Nelwan, Laurentius A. Pramono, Anna M. Lubis, Zubairi Djoerban*

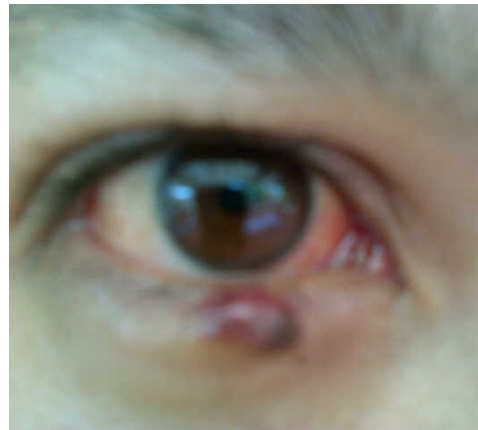Department of Internal Medicine, Faculty of Medicine, Universitas Indonesia – Cipto Mangunkusumo Hospital, Jakarta, Indonesia.

**Correspondence mail:**

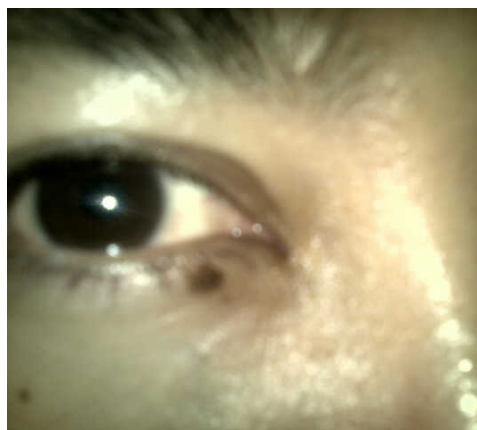
*Division of Tropical and Infectious Diseases, Department of Internal Medicine, Faculty of Medicine University of Indonesia – Cipto Mangunkusumo Hospital. Jl. Diponegoro no. 71, Jakarta 10430, Indonesia. email: ejnelwan@yahoo.com.*



**Figure 1.** Kaposi sarcoma in the right eye before received HAART



**Figure 2.** Kaposi sarcoma lesion was improved approximately within 1.5 months of Truvada® (emtricitabine and tenofovir disoproxil fumarate) and efavirenz therapy



**Figure 3.** Kaposi sarcoma lesion was healed within approximately 3.5 months of Truvada® (emtricitabine and tenofovir disoproxil fumarate) and efavirenz therapy

Kaposi sarcoma defined as a multifocal lesion in mucocutaneous sites which has low-grade malignant potential. Kaposi sarcoma also commonly found in visceral organs.<sup>1</sup> This malignancy is very popular among elderly men before the epidemic of HIV/AIDS in the decade of 1980-1990.<sup>2</sup> Kaposi sarcoma known to be associated with immunodeficiency state as in HIV/AIDS patients.<sup>3</sup> Nowadays, incidence of Kaposi sarcoma has decreased in developed countries in the era of Highly Active Antiretroviral Therapy (HAART),<sup>4</sup> but still a big problem in resource-limited areas such as Sub-Saharan Africa.<sup>5</sup>

Eye is an unusual location for Kaposi sarcoma.<sup>1</sup> There are not many study published about eye involvement of Kaposi sarcoma. Kaposi sarcoma of the conjunctiva and ocular adnexa has been reported to be strongly associated with HIV/AIDS patients.<sup>1</sup> An old case report published Kaposi sarcoma in the eye of HIV negative patient, which stated as a unique case because of his good immunological performance.<sup>6</sup> It is reported from the study of HIV/AIDS patients in Argentina that Kaposi sarcoma in the eye found in 0,25% patients.<sup>1</sup>

This is a case of a young gay man/homosexual who has been previously diagnosed HIV/AIDS with absolute CD4 18 cells/uL. He has a lesion in his right conjunctiva describe as a red, edema/swelling non-tender nodule (**Figure 1**). He also has a similar tumour in his neck below his right ear and also in his belly. It is clearly diagnosed from clinical appearance and MRI of the orbita that he has Kaposi sarcoma in his right conjunctiva. The result of biopsy on the tumor below the right ear resulted as a Sarcoma kaposi with further examination showed a hemangio-endothelioma, intermediate, negative immunohistochemical staining for EGFR so therefore not eligible for anti EGFR targeting therapy. After a carefully evaluation he was put on HAART and within approximately 1.5 months of Truvada® (emtricitabine and tenofovir disoproxil fumarate) and efavirenz therapy, the nodule was reduced significantly (**Figure 2**), and by 3.5 months, the lesion was healed (**Figure 3**). Similar response found on the mass below his right ear.

Kaposi sarcoma is one of the most popular neoplasm found in HIV/AIDS patients.<sup>3,4</sup> Epidemiologic studies revealed that homosexual and bisexual HIV/AIDS patients have higher incidence of Kaposi sarcoma than intravenous drug user HIV/AIDS patients.<sup>3</sup> It is first described by Moritz Kaposi, a Hungarian dermatologist in 1872.<sup>2</sup> Kaposi sarcoma is described as an idiopathic multiple pigmented sarcoma. Kaposi sarcoma has several manifestations, i.e. mucocutaneous, nodal, oral, and visceral presentation.<sup>3</sup> Kaposi sarcoma in the eye is included as a mucocutaneous nodal. The lesion can be plaque-like, nodal, and may be ulcerated, bleed, and become a focus of secondary bacterial infection.<sup>3</sup>

The pathogenesis of AIDS-related Kaposi sarcoma is related with cytokines expression. HIV infection cause immune dysregulation by altering the expression of cytokines, including IL-1, TNF- $\alpha$ , and IL-6. In the in vitro studies, it has been shown that cytokines secrete a number of angiogenic growth factors (basic fibroblast growth factor). These factors, along with HIV proteins, induce and proliferate cells to become sarcoma cells. Integrins and apoptosis process are important factors for the proliferation and neovascularization of Kaposi sarcoma tumour cells.<sup>3</sup>

Kaposi sarcoma can be treated locally with intralesional vinblastine or bleomycin, radiotherapy, and electrochemotherapy. Systemic therapy include HAART and systemic chemotherapy such as with daunorubicin and pegylated liposomal doxorubicin.<sup>4</sup> Evidences shown that incidence of Kaposi sarcoma was reduced in resource-rich countries with the estimated range between 33-95%.<sup>4</sup> This phenomenon is related to the availability and the global use of HAART. But, more concern and action must be done in Sub-Saharan Africa because of the high incidence of HIV/AIDS and Kaposi sarcoma, and it's minimal availability to HAART.

The use of HAART can reconstruct immune system with resulting increase of CD4 count and reduce of opportunistic infections. HAART also stated has an anti-angiogenic effect.<sup>7</sup> HAART reduce HIV proteins and create better milieu to

the cytokines, with the clinical result decrease the incidence and heal Kaposi sarcoma lesion.<sup>7</sup> In many cases, just giving HAART can heal Kaposi sarcoma without local and systemic chemotherapy treatment. Our patient from benefit the effect of HAART by healing the Kaposi nodule in his conjunctiva and now his absolute CD4 reached 386.

## REFERENCES

1. Pantanowitz L, Dezube BJ. Kaposi sarcoma in unusual locations. *BMC Cancer*. 2008;8(190):1-9.
2. Dalglish AG. Kaposi's sarcoma. *Br J Cancer*. 1991;64:3-6.
3. Thomas S, Java A. HIV-associated Kaposi's sarcoma. *Hospital Physician*. 1990;22-32.
4. Ferla LL, Pinzone MR, Nunnari G, Martellotta F, Lleshi A, Tirelli U. Kaposi's sarcoma in HIV-positive patients: the state of art in the HAART-era. *Eur Rev Med Pharmacol Sci*. 2003;17:2354-65.
5. Semeere AS, Busakhala N, Martin JN. Impact of antiretroviral therapy on the incidence of Kaposi's sarcoma in resource-rich and resource limited settings. *Curr Opin Oncol*. 2012;24(5):522-30.
6. Ron IG, Kremer I, Lowenstein A, Chaitchik S. Conjunctival involvement in classic (indolent) HIV negative Kaposi's sarcoma. *Br J Ophthalmol*. 1994;78:489-90.
7. Stebbing J, Portsmouth S, Gazzard B. How does HAART lead to the resolution of Kaposi's sarcoma? *J Antimicrobial Chemother*. 2003;51:1095-8.